

Cutaneous sinus tracts: An endodontic approach

Author_Prof Philippe Sleiman, Lebanon

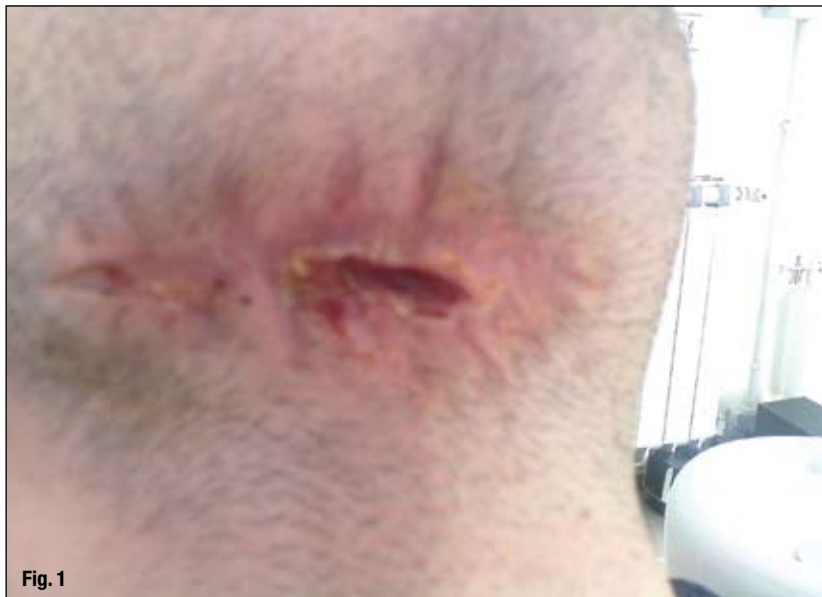

Fig. 1

Fig. 1 Post-op photo one week after external surgery to remove the patient's sub-mandibular gland.

_Misdiagnosis of an extra-oral sinus tract usually leads to a destructive invasive treatment of the local skin lesions that is not curative and often mutilating (Fig. 1). Attempting to treat such lesions with a circular incision of the orifice of the cutaneous fistula and excision of its entire tract with all the ramifications is not consistent with the present standard of care. Unfortunately, cutaneous fistulae are sometimes treated as though they are independent dermatologic lesions with the pathogenic characteristics and treatment prognosis typical for mucosal fistulae. However, even skin biopsy may produce unnecessary scarring.

Correct diagnosis is the key to treating this kind of lesion. A gentle digital finger pad pressure on the apical region of the area suspected can create a discharge of pus. A DentaScan can provide reliable information that will help with the final diagnosis and the subsequent treatment plan. A correct diagnosis will lead to a simple, yet effective treatment—the removal of the infected pulp canal tissue from the

root canal space—resulting in minimal cutaneous scarring.¹⁵

Cutaneous sinus tracts of dental origin have been well documented in the medical literature,^{1–7} dental literature,^{8–14} and dermatological literature. However, these lesions continue to be a diagnostic dilemma. Patients suffering from cutaneous fistulae usually seek treatment from a physician or a plastic surgeon instead of a dentist and often undergo multiple surgical excisions, multiple biopsies and antibiotic regimens with eventual recurrence of the cutaneous sinus tract because the primary dental cause is frequently misdiagnosed.

The evaluation of a cutaneous sinus tract must begin with a thorough patient history and awareness that any cutaneous lesion of the face and neck could be of dental origin.^{1,4,7} The patient's history may include complaints of dental problems. However, patients may not have any history of an acute or painful onset. There may also be complaints of episodic bleeding or drainage from the cutaneous site with persistence of the cutaneous lesion. Occasionally, there is a history of injury to the tooth.

Correct diagnosis of the cutaneous sinus of dental origin should be suspected by the gross appearance of the lesion. These cases typically present as erythematous, symmetrical, smooth, non-tender nodules of 1 to 20 mm in diameter with crusting and periodic drainage in some cases. The most characteristic feature of the nodule is its depression or retraction below the normal surface.¹⁵ This cutaneous retraction or dimpling is caused by the fixation of the tract to the underlying tissues and may be secondary to the healing process or a late finding in active disease. Lesions that previously underwent biopsy and treatment are usually characterised by the absence of at least part of the nodule and frequently by an orifice of draining sinus at the base of the fixed depression.¹⁵

Endodontic infection, the product of cellular degeneration—bacterial toxins—and, occasionally, the bacteria themselves within the canal spread through the apical foramen into the surrounding tissue. Thus, a slow inflammatory process begins in the tissue contained within the periodontal ligament. Left to itself, it may manifest in a variety of ways, ranging from simple widening or thickening of the ligament to granuloma or cyst. Sometimes a fistula may develop, with the patient reporting intermittent discharge of pus.

The fistula provides a means of continuous drainage of the lesion. The opening of the fistula may be found on the mucosa overlying the tooth that sustains it, but often it may also be found at a considerable distance from the diseased tooth. In some cases, the fistula may run in the space of the periodontal ligament of the same tooth. It may even traverse the periodontal ligament of the adjacent healthy tooth, thus simulating a lesion of periodontal origin. In such cases, negative pulp tests performed on the crown of the tooth, indicated by a gutta-percha cone inserted into the fistula, assist in making the correct diagnosis.

If the drainage of the fistula is not continuous but intermittent, it is preceded by a slight swelling of the area as a result of the increased pressure of pus behind the closed orifice. When the pressure becomes strong enough to rupture the thin wall of soft tissue, the suppurative discharge issues externally through the small opening of the fistulous orifice. This orifice may heal and then re-close, only to re-open later. The discharge of pus is never accompanied by intense pain. At most, the patient will complain of slight soreness in the area prior to reopening of the external orifice. The pus creates a tract in the surrounding tissues, following the locus minoris resistentiae. It may exit, at any point, in the oral mucosa or even in the skin. It is not uncommon, particularly in young patients, to find a cutaneous fistula at the level of the mental symphysis, if lower incisors are involved, or in the sub-mandibular region, if a lower first molar is involved. Also, it may be found in the floor of the nasal fossa, if a central incisor is involved.

Attempts to treat cutaneous fistulae with a circular incision of the orifice of the cutaneous fistula and excision of its entire tract with all the ramifications cannot be considered to comply with the present standard of care and should be regarded as highly undesirable. Most of the time, root canal therapy is the ideal treatment for such lesions. However, Grossman⁵ states that such tracts are lined by granulation tissue. In his study, Grossman was unable to identify any epithelium at all. Bender and Seltzer²² also conducted histological studies of numerous fistulous

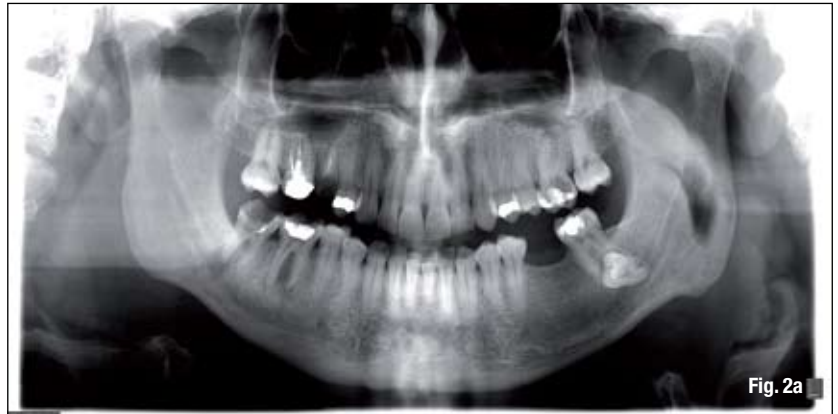

Fig. 2a

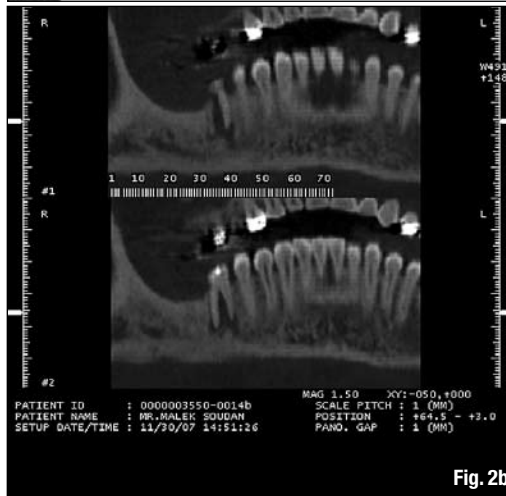

Fig. 2b

Fig. 2a_Panoramic X-ray showing some bone rarefaction under teeth 47 and 46.

Fig. 2b_Sagittal slide showing the lesion around the distal root of tooth 47.

tracts without finding an epithelium lining. Given the current state of knowledge and scientific data, there is no reason to recommend surgical removal of such tracts, just as there is no reason to believe that even epithelium-lined fistula tracts should not heal after appropriate endodontic therapy.

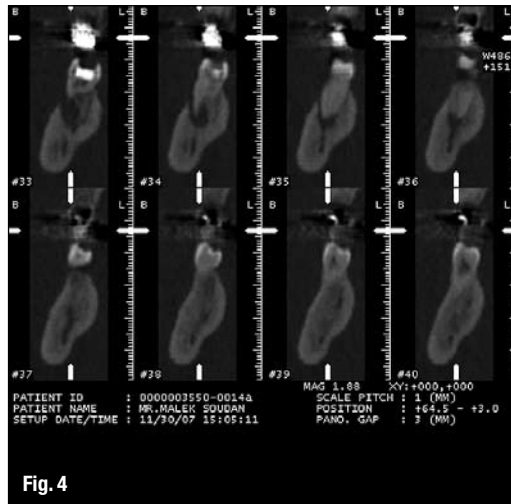
Obviously, these fistulae must be distinguished from congenital fistulae of the neck, both lateral—arising from the second brachial cleft—and medial—arising from rests of the thyroloassal duct—which

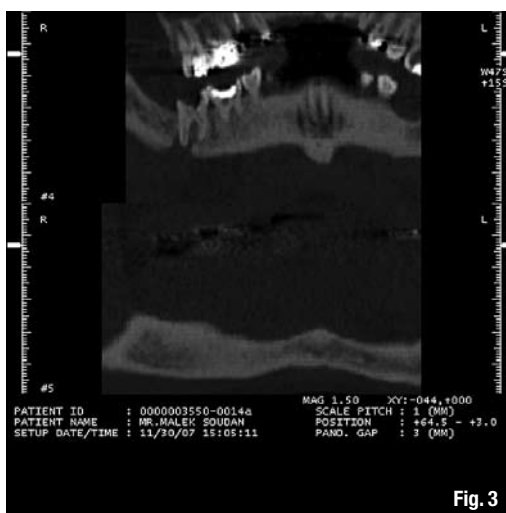

Fig. 3

Fig. 3_The mesial root of tooth 46 showing apical radiolucency, invading the tract of the lower mandibular nerve (014).

Fig. 4_Axial slide under tooth 46.



are lined by an epithelium. Such fistulae are of a different pathogenesis and definitely do not resolve spontaneously but only after careful surgical excisions of the tract.

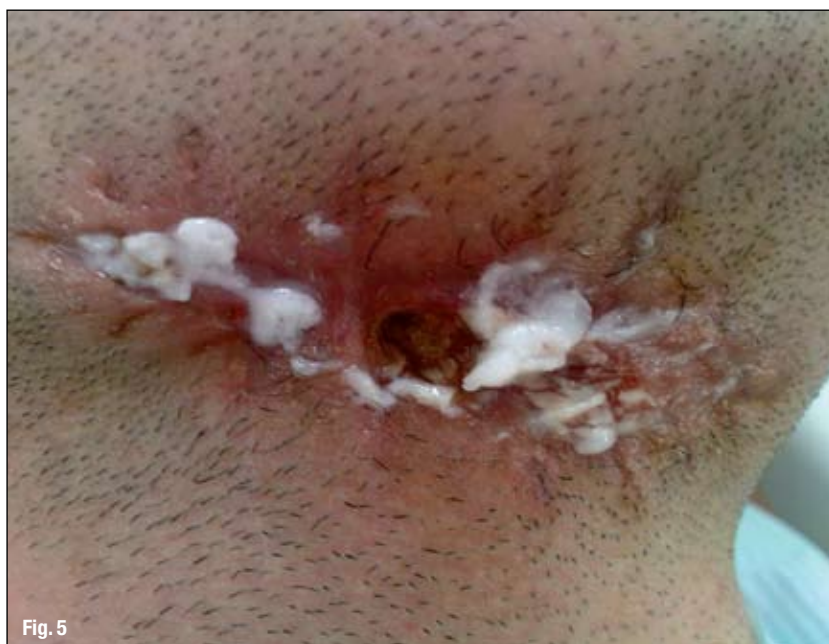The differential diagnosis of the case in question included the following:

- _localised infection of the skin, such as pyoderma, pimples, ingrown hairs and obstructed sweat glands;
- _traumatic or iatrogenic lesions;
- _osteomyelitis;
- _tuberculosis; and
- _actinomycosis.

_Case presentation

Fig. 5_One week after steroids and antibiotic treatment.

The patient was referred to me from overseas with a large mandibular fistula, which had previously been



misdiagnosed as an infection of the sub-mandibular gland. Surgery had been performed and his sub-mandibular gland had been extracted. The wound had not healed and the clinical situation was fast worsening. Thus, the wound had opened and sub-infected with a heavy discharge of pus.

A dentist invited to see the patient immediately telephoned me and sent a photo of the wound to me via his mobile phone. Following my recommendation, the patient was immediately put under double antibiotic therapy (Amoxicillin 1000mg twice daily, Metronidazole 500mg twice daily). The patient presented to my clinic the following day, where we started with a detailed questionnaire to collect all the information about the history of the wound. The patient reported that he had been suffering from this fistula for quite some time already with intermittent phases of discharge of an exudates and numbness of the lower lip. No dental pain was reported.

A panoramic X-ray showed some bone rarefaction under teeth 47 and 46, but no invasion of the mandibular nerve tract was evident (Fig. 2a). A dental scan with 0.5 mm increment was performed in order to gain a better idea of the clinical situation. One of the sagittal slides (013) clearly shows the lesion around the distal root of tooth 47, surrounding the apical part and destroying the cortical bone invading the lower soft tissue (Fig. 2b). Furthermore, the mesial root of tooth 46 showed apical radiolucency, invading the tract of the lower mandibular nerve (014; Fig. 3). This pathology explains the numbness of the lower lip, while the pathology around the distal root of tooth 47 explains the extra-oral fistula.

Careful review of the axial slides in the area of tooth 47 (006) offers an idea about the amount of bone destruction in the lower lingual area. The axial slide under tooth 46 reveals the communication between the lesion under the mesial root and the mandibular nerve tract (Fig. 4).

Next, we established a clear diagnosis that the lesion was an extra-oral cutaneous fistula of dental origin. The patient was suffering from a large, infected open wound and a suitable treatment plan had to be established quickly. The following solutions were presented:

1. Extraction of the teeth and curettage of the area, with extra attention paid to the mandibular nerve: This plan could provide the patient with a solution for eliminating the infection and allowing the wound to heal. Yet, two strategic molars would be lost with this solution and a replacement would not be an easy job with this amount of bone destruction in an infected area.

2. More conservatively, a root canal treatment in order to clean and disinfect the root canal systems of the two molars, followed by an internal medication and a 3-D obturation capable of blocking the bacteria from reaching the apical part and trapping the remaining bacteria inside the root canal system: This approach would allow the patient to keep his molars and would provide an environment in which the healing process could begin. The risk would be the establishment of an external biofilm that cannot heal by itself and may require microsurgical removal.

The patient and I decided to preserve the two molars. Immediately, root canal treatment, cleaning and shaping of the canal space using TF files (Sybron-Endo) with copious and alternate irrigation of Chlorhexidine, SmearClear (SybronEndo), distilled water, and sodium hypochlorite with ultrasonic activation in a well-established sequence, was performed. An apical enlargement to size #40 in .04 taper was performed after crown down with K3 files (SybronEndo), to disturb the biofilm mechanically and to help reduce the colony formation unit (CFU).

An intermittent paste was injected inside the shaped root canal system. The paste of two different antibiotics (Augmentin and Metronidazole) was manually mixed and injected with a paste filler. A hermetic temporary filling was placed for a week. The wound was covered with a dressing of steroids and antibiotic paste to prevent further external infection. A week later, the patient was already showing good progress. The wound had started to close and less inflammation and swelling were observed (Fig. 5). The root canal was reopened and cleaned, and no internal fluids were coming from the peri-apical region. RealSeal material was used as obturation material in a vertical condensation using RCP SL (Hu-Friedy) and an immediate build-up was performed. Thereafter, the patient was invited for regular control check-ups. A few weeks later, a post-op X-ray (Fig. 6) and photos were taken. The wound seemed to be in good condition and some skin and fibrous tissues were forming.

While I was writing this article, the patient visited Beirut and decided to come in for a check-up. He complained of a muscle disturbance of his lower lip, but all the previous numbness had disappeared. He agreed to perform an i-Cat scan in order to find out what was going on and to detect any pathology. I was amazed by the bone formation and complete healing (Figs. 7–9). The wound had also healed very well (Figs. 10a & b). I contacted a plastic surgeon and asked his opinion regarding the muscle disturbance. He posited that such symptoms may be caused by the tremendous loss of structure.

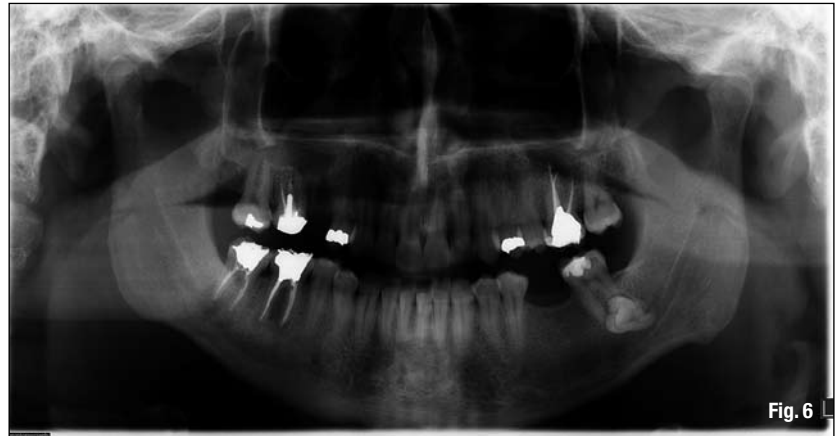


Fig. 6

Fig. 6 Post-op X-ray a few weeks after treatment.

Figs. 7–9 i-Cat images showing good bone formation and complete healing.

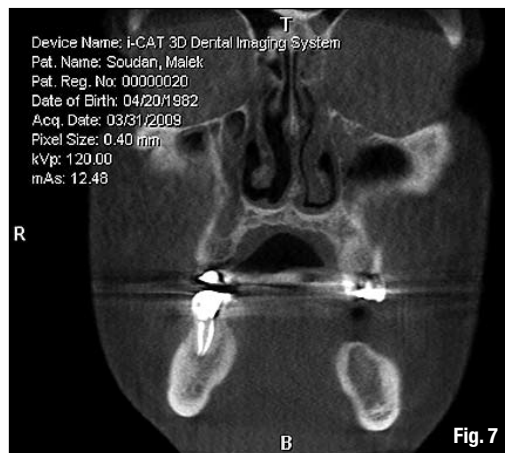


Fig. 7

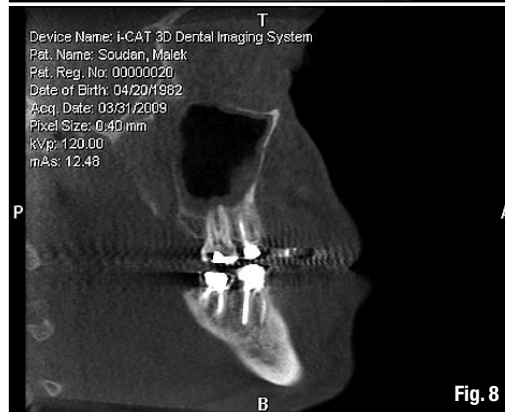


Fig. 8

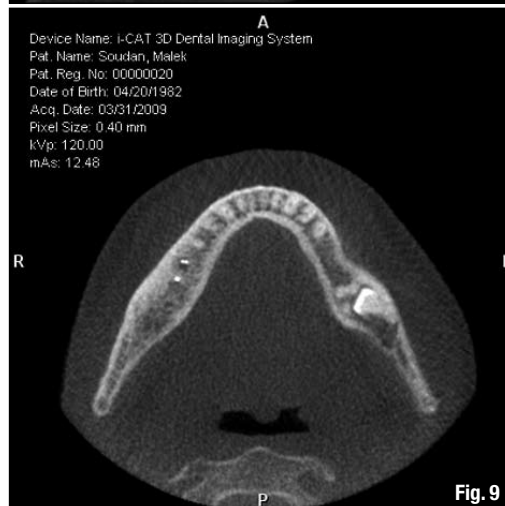

Fig. 9

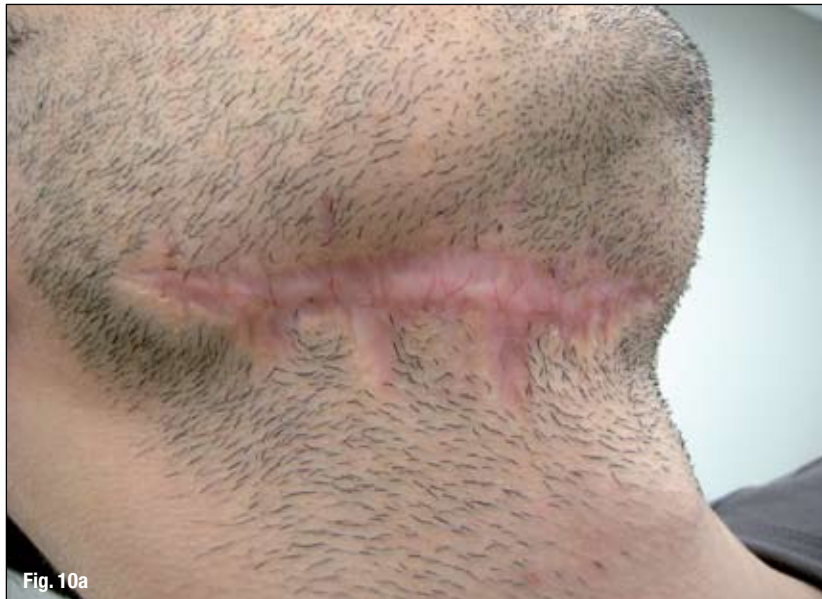

Fig. 10a

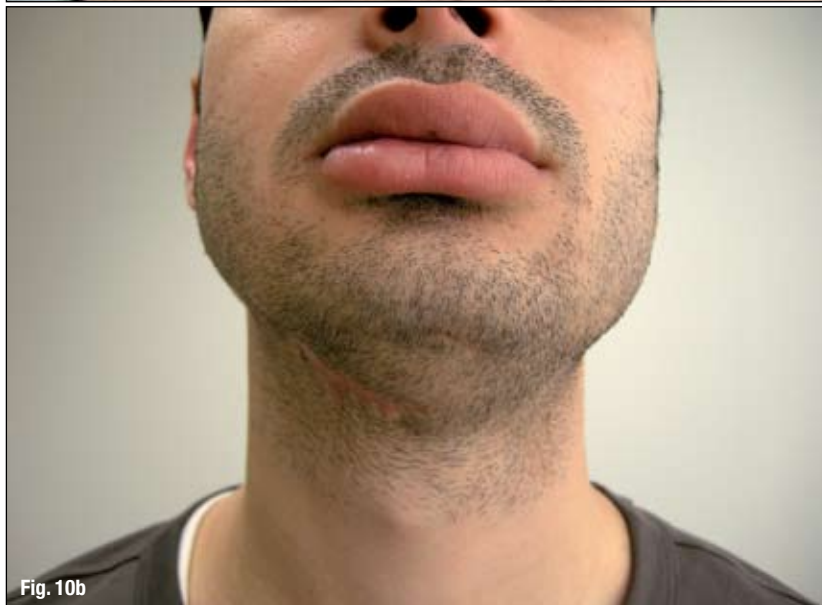

Fig. 10b

Figs. 10a & b Post-op wound healing.

_Discussion

An important diagnostic modality is the determination of the nature of fluid draining (if any) from the cutaneous sinus. During palpation, an attempt should be made to milk the sinus tract.

Any discharge obtained should be scrutinised to determine its nature (saliva, pus or cystic fluid).^{7,18} Culture and sensitivity testing of the fluid should also be performed to rule out fungal and syphilitic infection.⁹

Laskin¹⁷ elaborates on the physiological and anatomical factors that influence the spread and ultimate localisation of dental infections. Stoll and Solomon¹⁵ also emphasise that the ultimate path of the sinus (irrespective of the source) depends on several factors: most importantly, the anatomy of the tooth involved, muscular attachments to the jaw, fascial planes of the neck, and involvement of permanent or deciduous teeth. Cutaneous rather than intra-oral lesions are likely to occur if the apices of the teeth are superior to the maxillary muscle attachments or inferior to the mandibular muscle attachments.⁴

A pustule is the most common of all purulent draining lesions and is readily recognised by its superficial location and short course.¹⁸ Actinomycosis exhibits multiple draining lesions and characteristic fine yellow granules in the purulent discharge. The tooth is often not involved radiographically.¹⁸ If a sinus tract does not close after appropriate removal of the primary cause, the most common alternative cause is actinomycosis.¹⁰

The challenge in these kinds of cases is to assemble all the pieces of the puzzle and build up a full idea of the clinical situation. Assembling the pieces means that all the diagnostic materials, such as a history questionnaire, X-rays, CT scans, and sometimes biopsy and bacteria culturing, must be provided in order to establish a correct diagnosis. Most of the time, the solution will only be a simple routine that must be performed in certain conditions. Turning to solutions that are more complicated—and that certainly can be more profitable—is not always the right choice, nor the most ethical one.

Editorial note: A complete list of references is available from the publisher.

_author info

roots



Prof Philippe Sleiman received his DDS from the Lebanese University School of Dentistry in 1989. He conducted a DES in the endodontic programme at St Joseph University and a PhD at the Lebanese University Dental School. He has authored several international articles. He has his own line of instruments with the Hu-Friedy company and contributed to several project developments, and he has lectured internationally. Prof Sleiman is an instructor at the Lebanese University and an international trainer for the University of North Carolina. He is a fellow in the ICD and the AAE. Prof Sleiman maintains a private practice in Beirut, Lebanon, and in Dubai, UAE.