

When flexibility and strength are key

Author_ Dr Philippe Sleiman, Lebanon

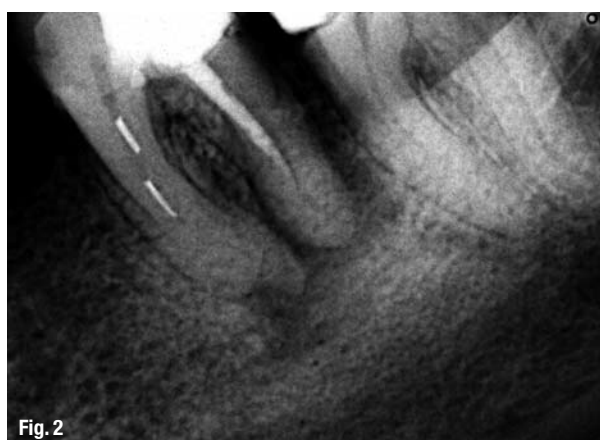

Fig. 2

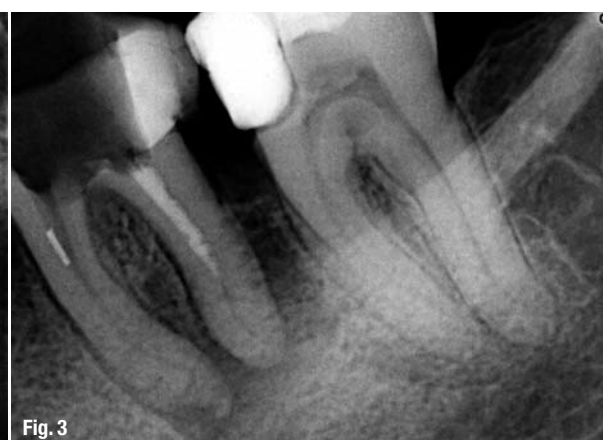

Fig. 3

_Root-canal retreatment is a very common procedure that endodontists and general practitioners are faced with on almost a daily basis. The biggest challenge here is to re-establish the initial pathway of the canal and its original exit or apex. During the past decade, several techniques required that gutta-percha be used to fill the root canals. Sometimes and for many reasons, such as leakage or short preparation and/or obturation, the gutta-percha needs to be removed and the canal renegotiated.

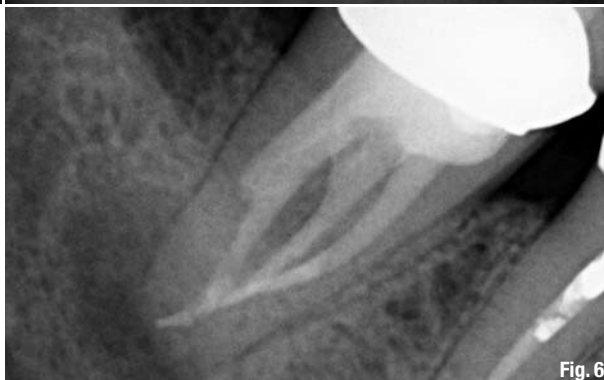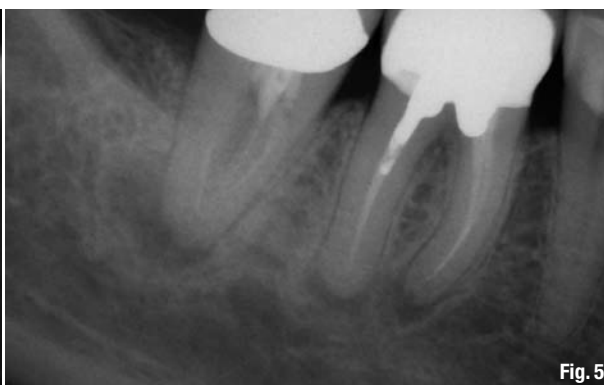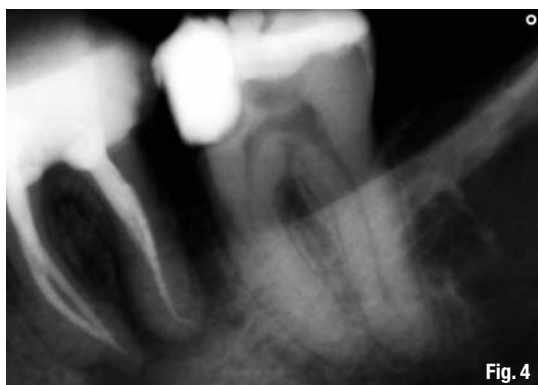Generally, NiTi rotary files were used in such cases in order to facilitate and expedite our task. However, the files used to accomplish this task faced additional challenges, that is, the debris coming from the previous obturation and the density of the obturation material. The first difficulty is piercing the mass of the obturation material. Here, our choice of file should focus on a strong tip that can take the pressure and engage the mass of the gutta-percha, break it down and push it back into the access cavity. The second challenge is to select an instrument that can enter the root-canal structure and engage the obturation material, pushing it out coronally, while offering enough flexibility to go around curves and shape the root-canal surface safely.

Today, thanks to heat treatment that has changed the world of rotary NiTi files, allowing us to modify the crystalline structure of the metal, we have been able to obtain several types of the alloy to give us different files, from the Twisted File to the latest modification of the K3 system, the K3XF (SybronEndo; Fig. 1). The K3 system files are known to be robust yet very safe. The slight modification in their structure gives these files much-needed flexibility, while preserving their very high safety levels.

The clinical applications are very simple. My favourite sequence of the K3 system is the G-pack, which allows me to do crown-down using the taper of the files and keeping the tip stable at ISO 0.25. This sequence allows for a very nice start, removing the obturation material from the coronal third with relatively short files, such as orifice openers, and doing so in a relatively short time. The deeper we go, the more we need to decrease the taper, especially when curves are present inside the canals and smaller taper files are needed. It is at this particular moment that the flexibility of the heat-treated alloy gives the files the ability to negotiate the curves without any distortion of the canal or macro-damage to the file structure (as has been demonstrated in research and clinically).




Fig. 1



Clinical cases

The first clinical case could be described as a very bad day in a dental office. Two files had been trapped and separated in the mesial canals and the patient was referred to the clinic but had to drive for more than two hours to get to our clinic. When I first saw the X-rays (Fig. 2), I remembered a very similar case from several years ago with practically the same location of file separation. The separated files in the mesial canals were clearly visible. It was also noticeable that the distal canal had not been treated to full length. Ultrasonic tips and the use of an operating microscope allowed me to retrieve the separated files and it was then time to reshape the canals and retreat the distal canal (Fig. 3). Owing to the combination of requirements for the treatment of this case—shaping and retreatment in one tooth—my instruments of choice were K3XF files. I started with 25.08, followed by 26.06 and concluded crown-down with 25.04. This gave access to the apical part, which was enlarged to 35.04 in the mesial and distal canals in order to prepare the apical portion of the root-canal system. The speed of the micromotor for the shaping procedure was 500rpm and a sequence of push-and-pull movements—four to five strokes per canal—with each file was used in order to reach full working length. Figure 4 shows the obturation of the canals, which was performed with RealSeal (SybronEndo) after both separated files had been removed and the root-canal system reshaped.

The second case came as another referral. The patient was suffering from pain in her lower molar and was sent to the office in order to check the case and give the necessary treatment. The preoperative X-ray (Fig. 5) showed an apical lesion with an incomplete root-canal treatment. Because diagnostics found no sign of a root-canal crack, retreatment was my choice. However, we had to overcome two obstacles: the crown placed on the tooth and the fibre post inside the distal canal. I decided to go through the crown without removing it in order not to place any tension on the distal canal. When analysing the anatomy, it appeared that the roots were fused. In such cases,

avoiding any tension is recommended in order to avoid any cracks.

Under the microscope and through the crown, I managed to remove the filling surrounding the post. With the use of the ultrasonic WHAT, I managed to remove the fibre post itself together with the previous filling from the access cavity. Using the K3XF after removal of the fibre post was a great help in reshaping the root-canal system, which appeared very convergent. The files displayed no sign of metal fatigue and the 25.06 was taken deeper into the canal compared with the standard K3 files. The extra flexibility and strength of the K3XF allowed me to perform crown-down and final apical shaping. Obturation of the root-canal system was performed with the Elements Obturation Unit (SybronEndo) and RealSeal material. The post-operative X-ray (Fig. 6) shows that the merging canals had been cleaned, shaped and filled; and the same had been done for the fibre-post space.

Conclusion

In the two clinical cases presented here—both rather a challenge for root-canal retreatments—the final results were an endodontic success. This lends support to the fact that each challenge needs to be treated separately without fear or tremor from the initial preoperative X-rays. Our fear shall control neither our judgment nor our choices!

I would like to thank Yulia Vorobyeva, interpreter and translator, for her help with this article.

_contact	roots
Dr Philippe Sleiman Dubai Sky Clinic Burjuman Business Tower, Level 21 Trade Center Street, Bur Dubai Dubai, UAE phil2sleiman@hotmail.com	