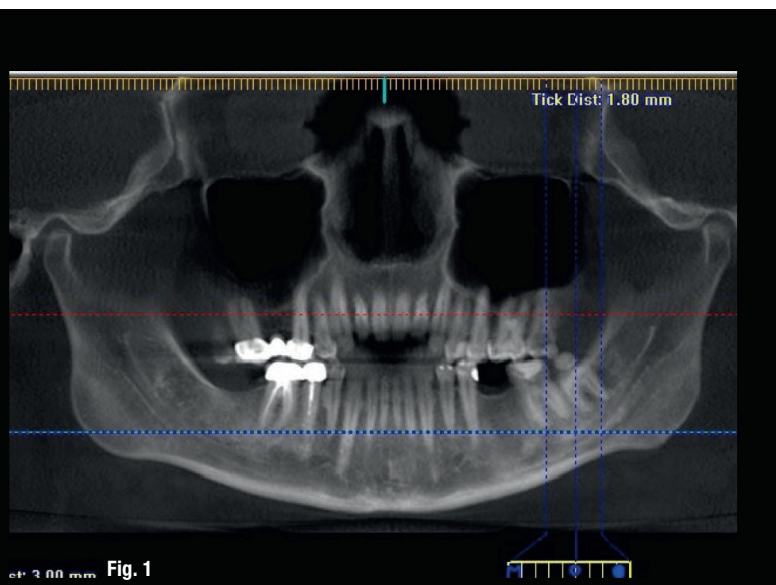


# Management of referred pain

Drs Chady Torbay, Sara Salloum, Claudia Dib, Edgard Jabbour & Philippe Sleiman, Lebanon



## Introduction

Referred orofacial pain, which is pain sensed at a site apart from the site of origin, is very frequent in dental clinics.<sup>1, 2</sup> As endodontists, the diagnosis of pain and successful pain management are our primary tasks. Pain referral undeniably has a neural basis. Specific passages and neural couplings in the brain and in the body are believed to lead to the probability of pain referral.<sup>3, 4</sup> As an illustration, some of the most enervating pain conditions that manifest initially as dental pain arise from the structures innervated by a common nerve network, the trigeminal system.<sup>5, 6</sup>

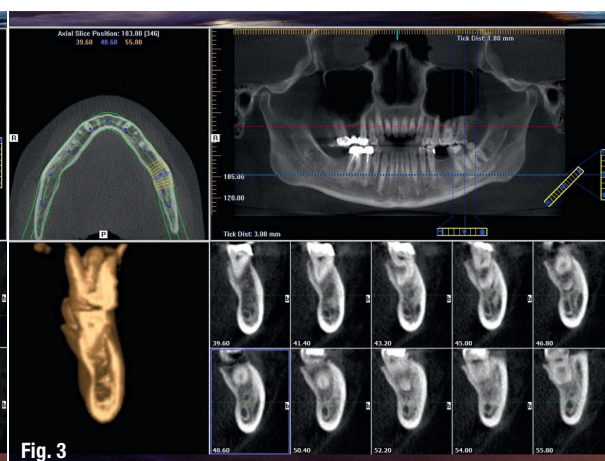
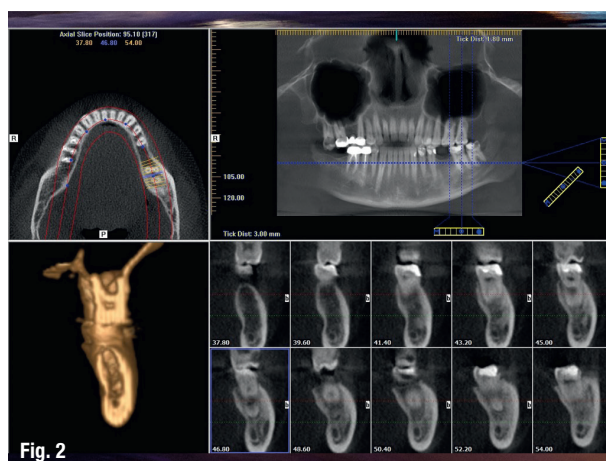
Referred pain can make diagnosis difficult and can result in off-target or wholly unnecessary root canal therapies, tooth extractions or surgeries. The incidence of dental-related pain during an acute myocardial infarction is a serious example of referred pain.<sup>7</sup>

Therefore, listening to the patient, obtaining a detailed dental history and collecting comprehensive diagnostic data are factors that improve the diagnosis of the problem before treatment initiation.<sup>8</sup> The most favourable therapy for referred pain is treatment of the cause of the symptom; this involves identification of the site of the primary disease, which may not be simple in all circumstances.<sup>9</sup> If the origin site cannot be identified, therapy is only symptomatic, with generally administered analgesic drugs. Certainly, adequate pain management is a compelling and universal requirement in health care.<sup>10</sup> For this reason, collaboration between the departments of dentistry, pharmacology and physiology might be needed.<sup>11</sup>

In this report, we describe two cases of misdiagnosis and a delay of appropriate treatment, resulting in the excessive and ineffective use of drugs. In these, several oral health care professionals failed to diagnose the cause of persistent facial pain because of the inability to conduct a comprehensive dental examination. Furthermore, they failed to use new technology to aid diagnosis.

## Case 1

A patient suffering from what looked like facial myalgia was referred for consultation. He was a manager at a well-known medical hospital and had for several weeks suffered from extreme pain. His doctors thought that it



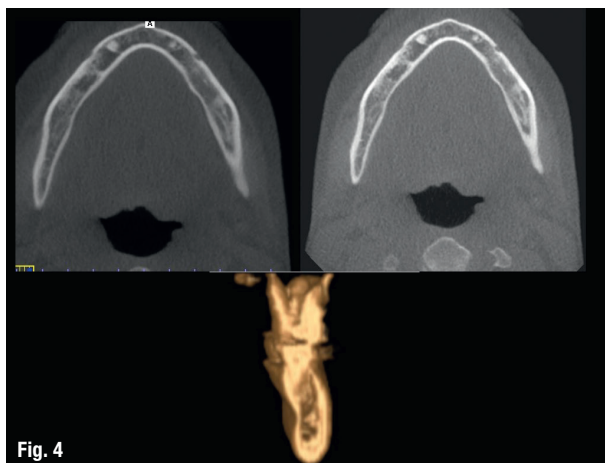


Fig. 4

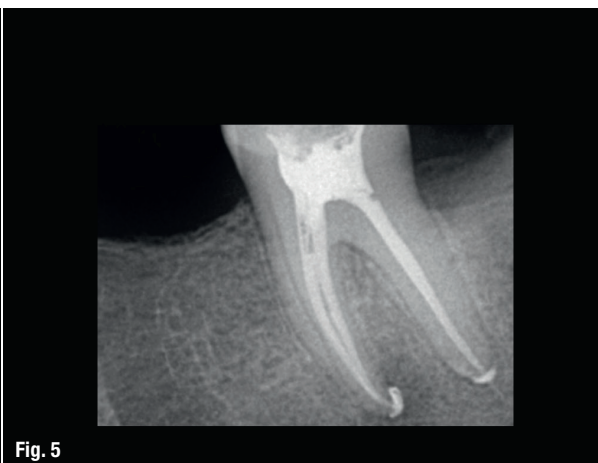


Fig. 5

was inflammation of the trigeminal nerve, and since analgesics and anti-inflammatories had had almost no effect, the patient was put on Tegretol. A friend advised him to seek a dental consultation just in case. A CBCT scan was taken to obtain adequate visualisation for diagnosis and a clinical examination was performed. Nothing specific was found, but the image around the third molar (Fig. 1) was suspicious. The surgeon thus suggested that it be extracted, but once the anaesthetic had worn off, the pain was still the same. I asked for a copy of the CBCT scan and was carefully looking over each tooth in the evening when something caught my eye under the second molar. From the axial views (Figs. 2 & 3) and the multiplanar reformatted (MPR) view (Fig. 4), it looked like a migrating infection from the molar going around the mandibular nerve and that may have been the cause of the pain, as the inflammation can exert pressure on the nerve, causing pain. I immediately called the patient and asked to see him as soon as possible in the morning. On his arrival, the first thing I did was to check the vitality of the tooth in question, as well as the rest of the dentition, both maxillary and mandibular. The mandibular second molar did not show any sign of vitality in response to heat, cold or electronic stimulus and was almost negative on percussion, which was curious. I explained the situation to the patient, and

he agreed that we do the drilling test, and it did not react at all. I opened the access cavity, and as soon as I began testing the permeability on the distal canal, the patient began experiencing severe throbbing pain that radiated to the left of his face. A few seconds later, inflammatory liquid started draining from the distal canal, and I used the MacroCannula of the EndoVac (Kerr) to help it drain faster. The drainage lasted almost 15 minutes. Once it had stopped, the patient felt some relief, but he asked for a pause in treatment, as the pain was intense. We agreed not to finish the treatment in the same day and that I would see him the following day, and he promised to keep me posted during the day. After taking a long-deserved nap, he called me and told me that he felt like a normal person again. All medications were stopped—he was feeling peculiar from the Tegretol—and the next day I finished the root canal therapy (Fig. 5) using TF Adaptive (Kerr) and the Sleiman sequence of irrigation with the EndoVac, followed by warm 3-D obturation of the root canal system, and later a crown was placed.

## Case 2

The patient was referred to the clinic suffering from pressure on a mandibular molar. She also described a burning sensation on her lower lip. A radiograph was

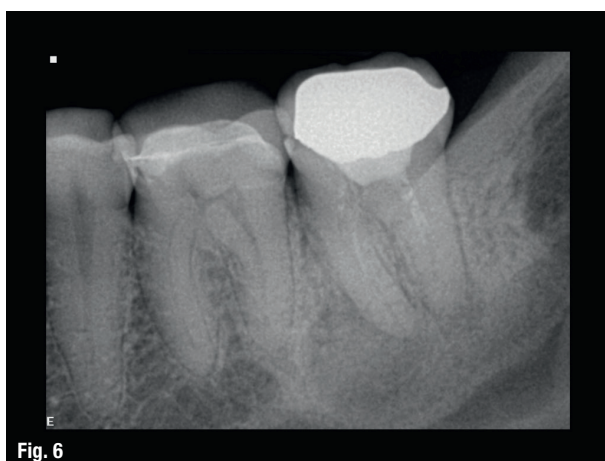

Fig. 6

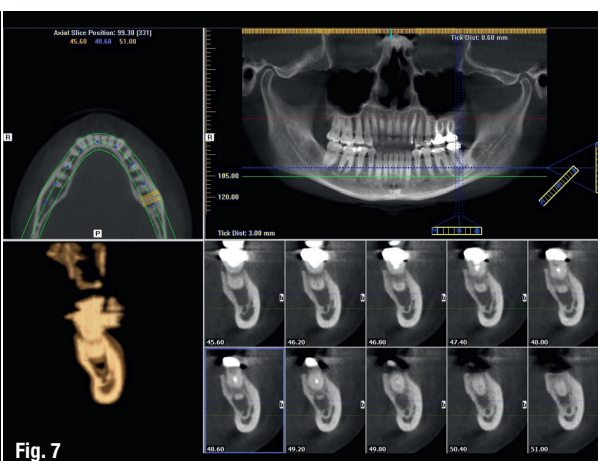


Fig. 7

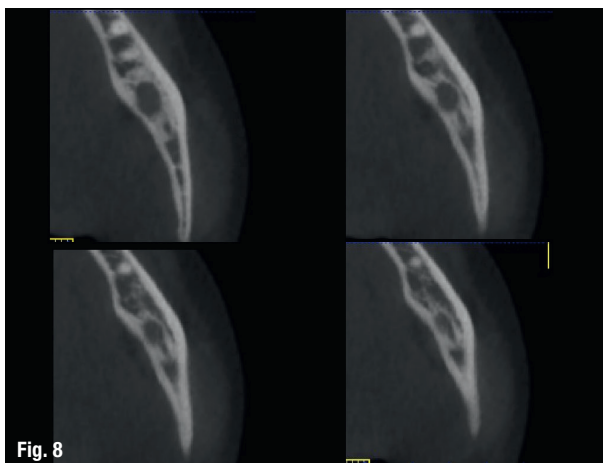


Fig. 8

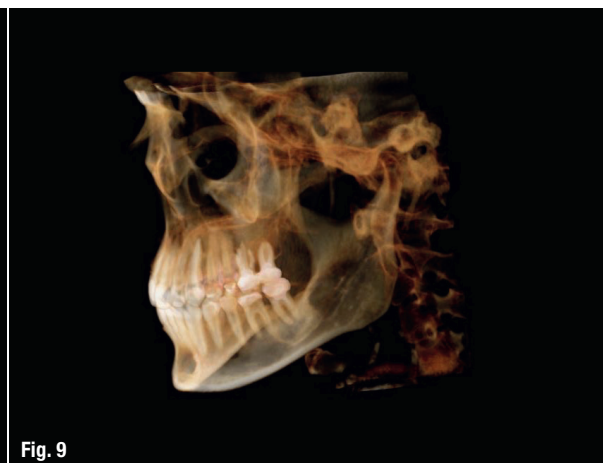

Fig. 9

taken (Fig. 6), and it showed an incomplete root canal therapy with a radiolucency in the apical area. I informed the patient that a CBCT scan would be essential in order to determine exactly what was going on. From the axial view (Fig. 7), we could see clearly the amount of bone destruction under the mesial roots in particular. Additionally, I noted that the bone covering the mandibular nerve had resorbed in certain areas, which could put the nerve in contact with the inflammatory liquid, causing what the patient described as a burning sensation. On the sagittal slices (Fig. 8), we could see the volume of the lesion and the intimate relation with the mandibular nerve. The 3-D reconstruction using Anatomage software revealed the volume of the lesion (Fig. 9). The lesion did not look cystic, as it was confined to the spongy bone, with no damage to the cortical bone lingually or buccally, and no defined borders. I advised the patient that we would need to put her on antibiotics 24 hours prior to the treatment as a precaution in order to try to minimise any flare-up, as such an occurrence would place more pressure on the nerve. The following day, the root canal therapy was performed using TF Adaptive and the Sleiman sequence of irrigation with the EndoVac, followed by warm 3-D obturation of the root canal system. During the use of negative pressure, a great deal of drainage continued for almost 10 minutes from the

mesial canals. Root canal therapy was performed in a single session (Fig. 10). Antibiotics were continued for seven days. Figure 11 shows a comparison between five weeks and immediately postoperatively. Figure 12 shows a comparison between five months and demonstrating that the healing process was proceeding well. Taken at the one-year follow-up, Figure 13 shows the beautiful healing and complete closure of the bone surrounding the mandibular canal. Figure 14 provides a comparison between the initial situation and the progress after one year.

## Discussion

Orofacial pain has been associated with many neurological diseases, as well as some cardiac problems.<sup>12</sup> In this paper, we discovered a low prevalence of referred dental pain, from the origin site of pain origin, evaluated through a tomographic scanner, to the other sites.<sup>13, 14</sup> The extended illness in the patient (case 1) was caused by a slip-up on the part of the treating dentist. Medical misinterpretations can have tragic effects on the lives of patients. Therefore, a standard and logical protocol should be followed in the hope that a correct diagnosis of pain can be made and the appropriate therapy directed to the source of pain and not the site of pain.<sup>15</sup>

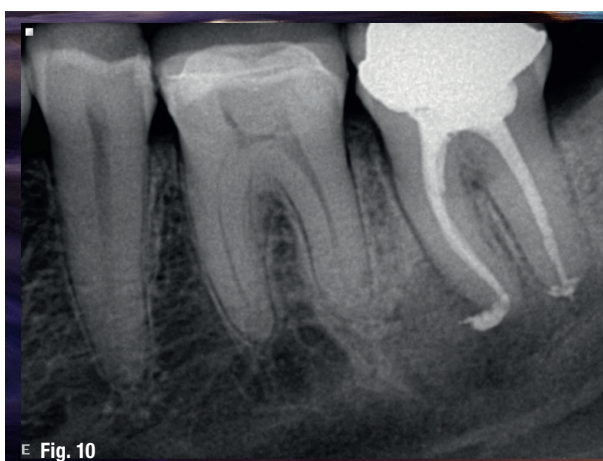

Fig. 10

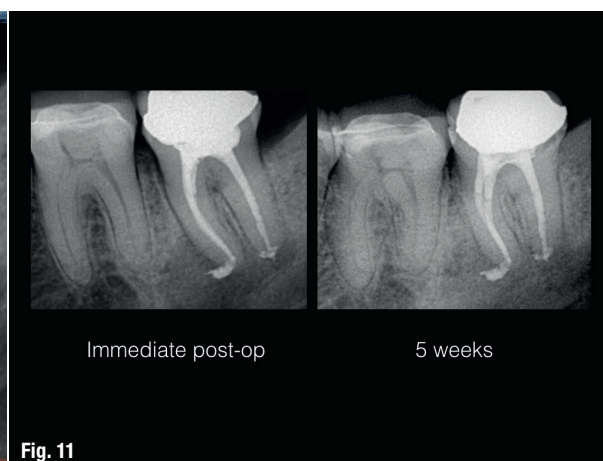

Fig. 11



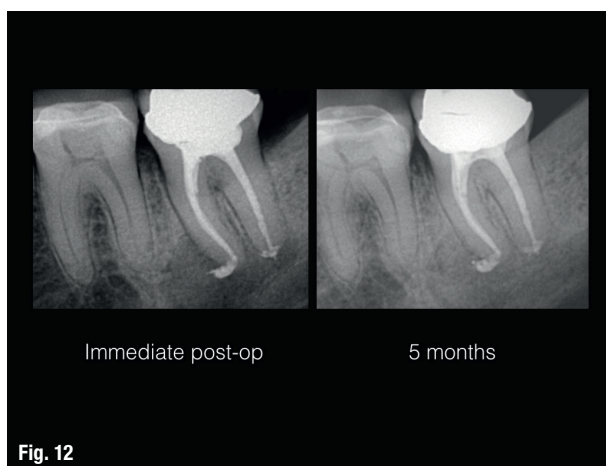


Fig. 12

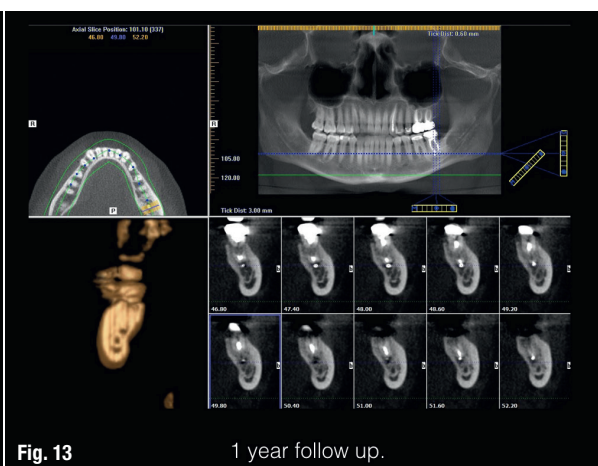


Fig. 13

1 year follow up.

Actively listening to patients is vital for both diagnosis and pain management. It is only through effective communication between both parties that dentists and patients can produce the best treatment plan. Equally important are a good knowledge of the facial anatomy, a carefully recorded medical history and a clinical examination including pulp tests and advanced radiographic techniques.<sup>16</sup> Likewise, shedding light on some factors that could play role in the occurrence of the referred pain might be beneficial.<sup>17, 18</sup>

Recurrent dental pain occurs the most in women, and this is in accordance with some reports indicating that women have a higher rate of some painful facial conditions.<sup>19, 20</sup> Recent medical evidence suggests that the trigeminal and vagus nerves are frequently viewed as pain mediations to the facial region.<sup>21–23</sup> Moreover, the differences in pain perception and the presence of proprioceptors in the periodontal tissue increases the probability of referred pain accompanying periapical lesions over the probability of such pain with periodontal lesions.<sup>24</sup>

Additionally, when suspecting referred pain of any unknown origin, it is the dentist's responsibility to refer the patient to the appropriate physician, providing a detailed report of the tests performed.<sup>25</sup> As the diversity of referred pain becomes more complicated across a wide range of situations, and the necessity to coordinate interaction among multiple disciplines becomes ever more important, combining well-functioning teams is a critical target throughout the health care system, especially when odontogenic causes of pain have been ruled out and non-odontogenic causes need to be considered. An interdisciplinary team is a one in which the team members include all kinds of medical specialists, not just dental ones.<sup>26, 27</sup> Researchers have suggested that working together decreases the potentiality of medical errors. Effective teams disintegrate hierarchy and concentrate the power of health care systems.<sup>28</sup>

However, under the mantra “the doctor knows best”, a physician may be hypnotised into thinking that asking

for a consultation or for more accurate diagnostic details, whether concerning equipment or experience, might be embarrassing and self-devaluing.<sup>29</sup> Moreover, professional custom often runs against obtaining second opinions, standing in the way of the best therapy.<sup>30</sup> Nevertheless, physicians should always prioritise the patient's welfare and ask for help if needed.<sup>31</sup>

*Editorial note: A list of references is available from the publisher.*

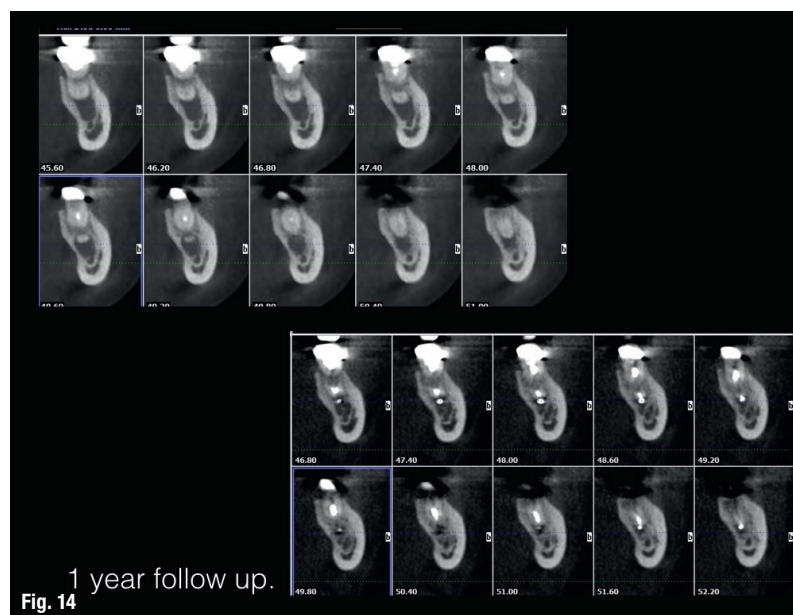


Fig. 14

1 year follow up.

## contact



**Dr Philippe Sleiman** is an assistant professor at the Faculty of Dentistry of the Lebanese University in Beirut in Lebanon. He can be contacted at [profsleiman@gmail.com](mailto:profsleiman@gmail.com).