

Root canal therapy and coronectomy

Drs Mirna Hobeika, Ali Hajj Hassan, Edgard Jabbour & Philippe Sleiman, Lebanon

Introduction

Coronectomy is a procedure that generally spares the vital coronal pulp and is performed to avoid the risk of damaging the inferior alveolar nerve (IAN) during the surgical procedure when extraction of mandibular third molars is indicated or needed. Coronectomy is the removal of the crown of the mandibular third molar without exposing the pulp.¹ The coronectomy procedure is performed only on the third molar crown, leaving the roots in the socket. This procedure is now known for its benefits and success rate, in contrast to the contemporary belief that the roots left behind will be a source of problems.² Risk factors for nerve injury include root proximity, the surgeon's experience, surgical procedures, the patient's age and pre-existing disease. Several studies have shown that coronectomy significantly decreases the risk of iatrogenic injury to the IAN and lowers the complication rate.³ Coronectomy has been associated with a low incidence of complications in terms of IAN injury (0.0–9.5%),

lingual nerve injury (0.0–2.0%) and pulp disease (0.9%),⁴ in addition to other rare events, such as swelling, fever, alveolitis, pulpitis and root exposure.⁵

Coronectomy to prevent IAN damage was first proposed by Ecuyer and Debien in 1984,⁶ and it remained controversial owing to the possibility of infection and other pathologies arising from the roots left behind.² Potential complications include deep dry sockets, local postoperative infections, postoperative pain, pulpitis, root canal necrosis and infection, and an increased risk of IAN infection, which is known as failed IANI.⁷

The point of discussion is whether it is necessary to perform root canal therapy simultaneously with coronectomy if the pulp is going to be exposed during the surgical procedure. A new method combining coronectomy with root canal therapy, when necessary, in order to decrease the risk of infection, pain and other complications is introduced in this paper.

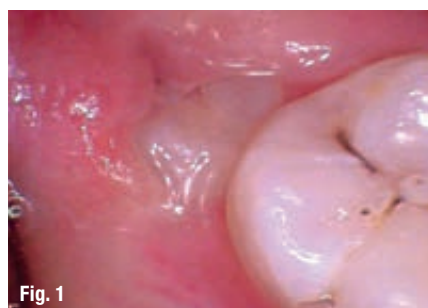

Fig. 1

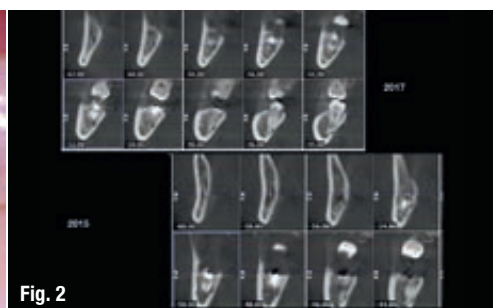


Fig. 2

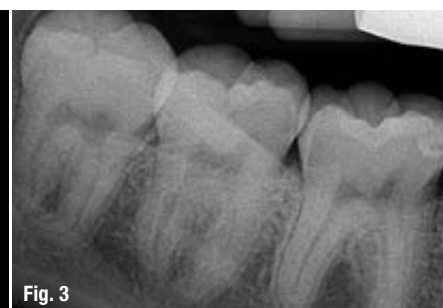

Fig. 3

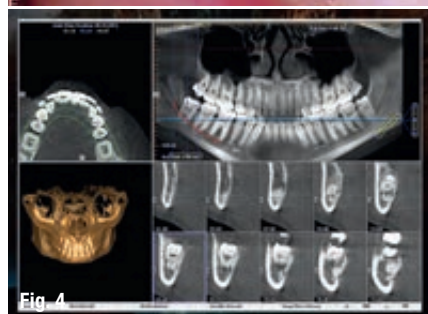

Fig. 4

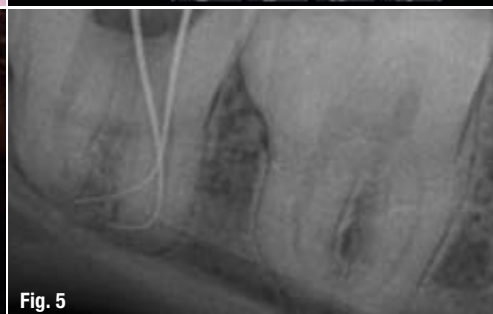

Fig. 5

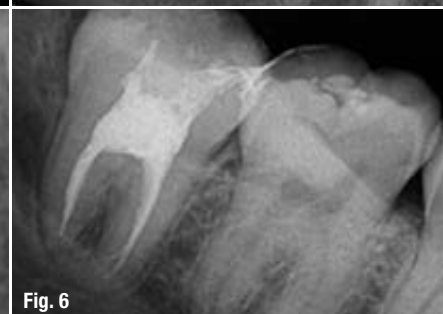

Fig. 6

Fig. 1: Partially erupted third molar and inflammation of the gingiva distally. **Fig. 2:** Pre-op radiograph showing a hook-like curve of the mesial root, as well as the relationship between the pulp chamber position and the bone level. **Fig. 3:** CBCT scans showing the intimate relation between the mesial root and the IAN and confirming the bone level relative to the pulp chamber. **Fig. 4:** File in a mesial canal showing the abrupt curvature. **Fig. 5:** A complete root canal therapy was performed. **Fig. 6:** Bitewing radiograph taken during the surgical procedure, showing the level of the surrounding bone and the remaining part of the tooth.

Bite wing to check the level of bone

Fig. 7

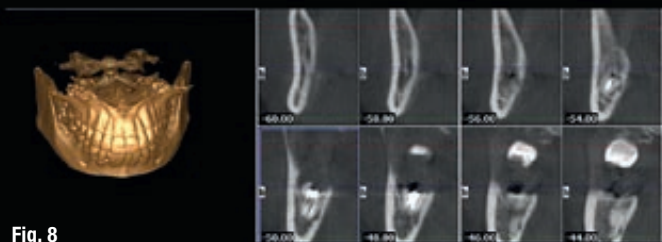
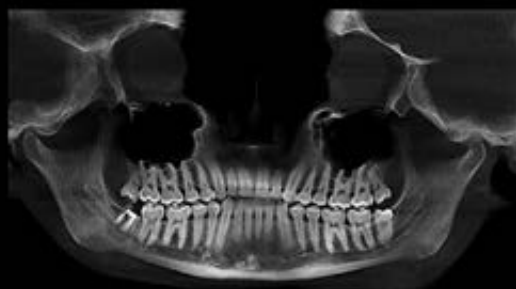

Fig. 8



2017

2015

Fig. 9

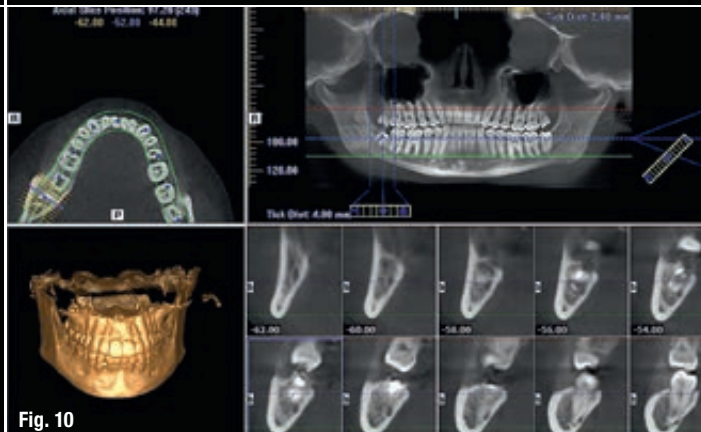


Fig. 10

Fig. 7: A small field of view CBCT scan confirmed the outcomes of the surgical procedure and root canal therapy. **Fig. 8:** Two-year follow-up radiograph. **Fig. 9:** CBCT scans showing the root migration above the nerve, allowing for safe extraction to be performed. **Fig. 10:** Comparison of the immediate post-op situation and the situation at the two-year follow-up.

Case presentation

A female patient in her mid-twenties was suffering from typical partially erupted third molar complications (Fig. 1). Extraction was advised in order to relieve the patient. A preoperative radiograph was taken (Fig. 2) for the surgeon and endodontist to discuss the shape of the roots and the IAN proximity. At the request of the endodontist, a CBCT scan was performed (i-CAT), as is advised prior to any surgery (Fig. 3). The cross sections revealed an intimate relation between the mesial root and the nerve, and thus indicated that any surgery at this point could cause some trauma to the nerve.

The situation was explained to the patient, who was very concerned about the potential injury to the IAN. However, the patient presented with acute pain, which would require treatment, possibly antibiotic therapy, which in the future would be her go-to in case of a flare-up. This was definitely not an ideal solution, especially in view of the efforts currently being undertaken by the European Society of Endodontology to limit antibiotic prescription for root canal therapy to a reasonable and evidence-based minimum. The alternative solution in such cases is coronectomy.

From discussing this option with the surgeon and studying carefully the radiographs and CBCT data, it was clear that, if the surgeon was to cut the crown below bone level, pulp exposure and partial pulpectomy were inevitable. Therefore, in order to minimise postoperative complications, the decision was made to perform a root canal therapy on the third molar to reduce the risk of pulpitis or infection in the apical part. The patient agreed to this solution.

Endodontic treatment was performed using the TF Adaptive SM (small/medium) procedure pack (Kerr) for

root canal shaping. During the treatment, one periapical radiograph was taken (Fig. 4) and it showed the curve on the mesial roots. Irrigation was performed very safely with the EndoVac unit (Kerr), as any extrusion of sodium hypochlorite could have severe consequences for the nerve and the apical area. The root canal therapy was completed in a single visit (Fig. 5), following which the surgeon performed the coronectomy. A bitewing radiograph was taken to check the level of the coronal part after the excision and confirm that it was completely under the bone level (Fig. 6). A reinforced glass ionomer was used to seal the roots and sutures were placed and left for one week. A small field of view CBCT was taken to check the post-operative outcome of the procedure (Fig. 7).

Two years after the treatment, the patient returned to the clinic complaining of some pressure sensations in the area. A CBCT scan allowed us to investigate the situation, and it revealed a pleasant surprise: the tooth had migrated coronally and gone above the nerve (Figs. 8 & 9). We explained to the patient that the remaining part of the tooth had moved towards the gingival level, which was why she was feeling pressure, and now it would be safe to remove the remaining tooth. The surgeon performed the intervention. Figure 10 shows how much the tooth had migrated over the two years and demonstrates the absence of any infection under the roots.

Editorial note: A list of references is available from the publisher.

contact

Dr Philippe Sleiman is an assistant professor at the Faculty of Dentistry of the Lebanese University in Beirut in Lebanon. He can be contacted at profsleiman@gmail.com.

