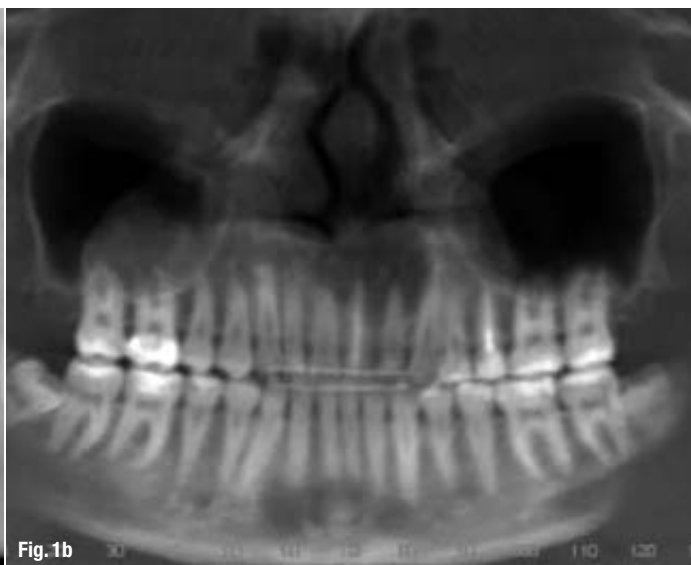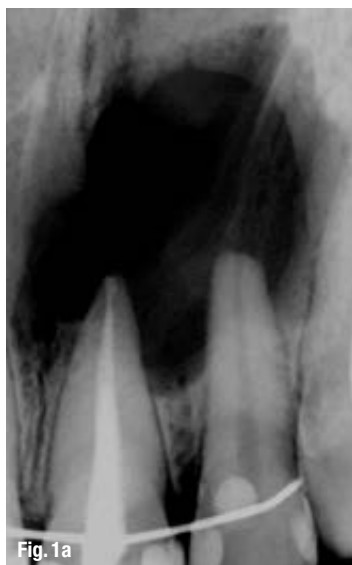


# Zero apicectomy in endodontic microsurgery

**Authors:** Dr Randa Harik, Dr Grace Issa & Philippe Sleiman, Lebann

## Case 1

**Figs. 1a & b:** Preoperative periapical (a) and panoramic radiographs (b).



## Introduction

Surgical endodontic treatment is a therapy modality for teeth with apical periodontitis and may be indicated for teeth that previously underwent an unsuccessful endodontic treatment, as well as teeth where a non-surgical approach has a high risk of failure.<sup>7,16,35</sup> The procedure usually consists of several steps and includes a retrograde obturation, which is performed after root resection followed by a retrograde preparation of the root canal.<sup>6</sup>

Also, presence of true apical cysts requires a surgical treatment as such cysts are less likely to heal by conventional root canal therapy because they are self-sustaining and no longer dependent on the presence or absence of root canal infection.<sup>10,30,28</sup> Accordingly, surgical intervention is necessary in the treatment of true apical cysts.<sup>17,23,27,29</sup>

The limitations of periapical radiography have led to significant interest in cone beam computed tomography (CBCT) in endodontic applications. It seems that the number of CBCT scans taken every year is growing as awareness and resolution are increased

and costs are reduced.<sup>32</sup> CBCT can be helpful, if not instrumental, in the differential diagnostics of cystic lesions. In particular, CBCT images can provide a moderately accurate diagnosis between cysts and granulomas.<sup>15</sup> Simon et al found that the CBCT may provide a more accurate diagnosis than biopsy and histology providing a diagnosis without invasive surgery and/or waiting a year to see if nonsurgical therapy is effective.<sup>33</sup>

In this article, we will describe a new approach in surgical endodontics that focuses on preserving the integrity of the apical part of the root and removing the cyst or cysts completely. We will illustrate this approach with a series of cases showing preoperative condition and postoperative healing.

## Zero apicectomy technique

When a patient presents with signs of cystic reaction as evident on the periapical X-ray, a radiolucent lesion involving the apex, with clear radiopaque borders, demonstrating signs of PDL disruption and following signs confirmed by clinical examination that include negative pulp vitality tests, slight mobility as

necrotic pulp signs, presence of cystic liquid drainage when opening the access cavity, a surgical intervention is indicated, and zero apicectomy may be an approach of choice.\*

Additionally, such signs as presence of fistula, presence (and recurrence) of swelling with a balloon effect under digital pressure, history of preceding unsuccessful treatment are considered as confirmation of a true apical cyst.

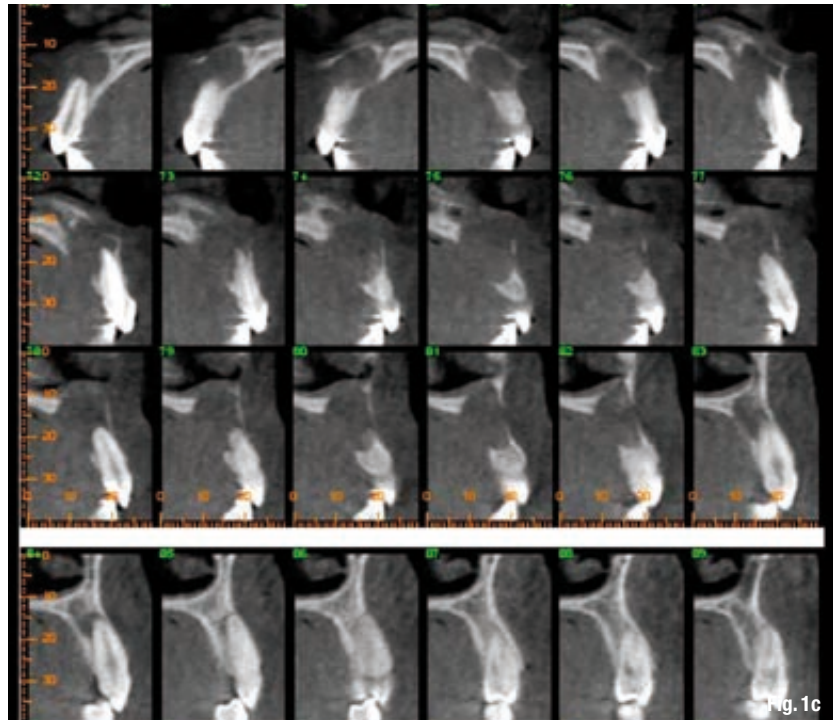
To ensure all diagnostic findings are included, a CBCT scan is performed and evaluated for patients presenting in such status.

When presence of cystic lesions is confirmed and the diagnosis is explained to the patient alongside with treatment options, informed consent for the combined RCT+apical surgery treatment is obtained.

Patients are scheduled for the intervention and instructed to take the first dose of antibiotic medication 1 day before the appointment. Additionally, 30 minutes before the treatment begins patients are instructed to take 400 mg of ibuprofen.

The treatment is performed under local anesthesia with adrenaline 1:100,000, infiltrated under the periosteum. However, if there is no fistula associated with the cystic lesion in question, it may be beneficial to start by opening the access cavity to allow for drainage and decrease of pressure in the lesion, thus making the following anesthesia injection safer.

We then proceed by isolating the tooth or teeth with a rubber dam and move on to access cavity preparation followed by shaping and cleaning the root canal system via an orthograde access. Conventional root canal therapy is a prerequisite for a successful same-session zero apicectomy.



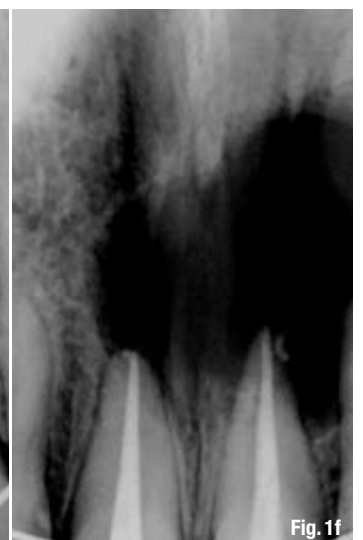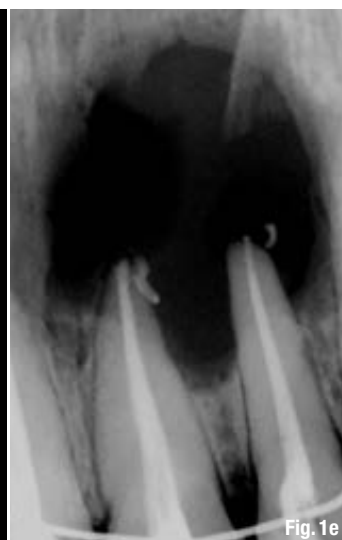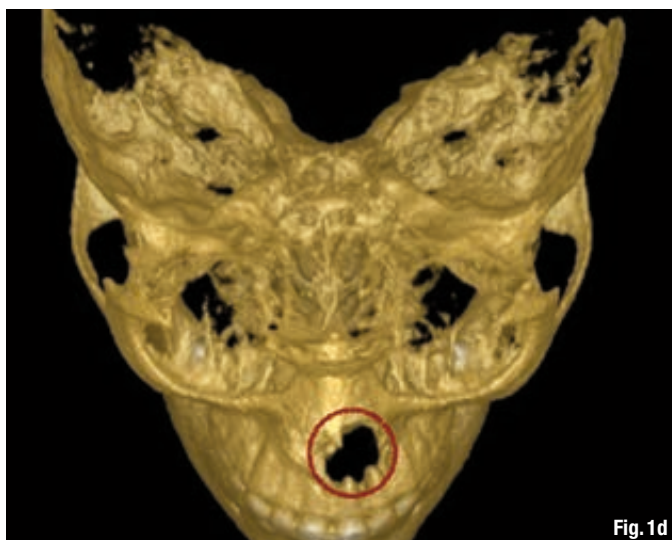
**Fig. 1c:** CBCT axial slices.

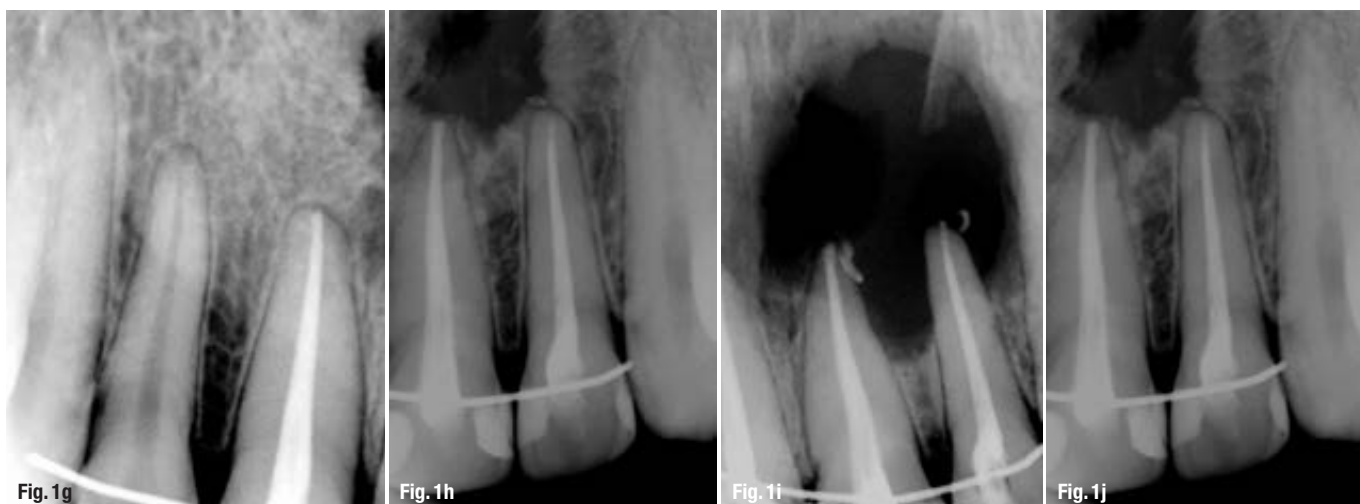During RCT, irrigation is conducted with the negative pressure technique EndoVac (Sybron Endo) as the system delivers irrigants safely to the apical terminus of root canals.<sup>25</sup> The irrigation is conducted according to 'A' sequence of irrigation alternating sodium hypochlorite, sterile water (or saline), and EDTA.<sup>34</sup> As soon as the working length is determined electronically, the irrigation micro-cannula can be placed at the working length,<sup>25</sup> ensuring a thorough cleaning of the apical third and the apex.

After the preparation and irrigation stages are completed, a temporary filling is placed in the access cavity, and the rubber dam is removed. The obturation of the canal is deferred, as the canal cannot be properly dried at this stage.

**Fig. 1d:** CBCT 3-D reconstruction demonstrative the extent of the lesion(s).

**Figs. 1e & f:** Immediate postoperative radiographs of the left incisors (e) and centrals (f).





**Figs. 1g & h:** One-year follow-up.  
**Figs. 1i & j:** Comparison of immediate postoperative radiograph (i) with 1-year follow-up (j).

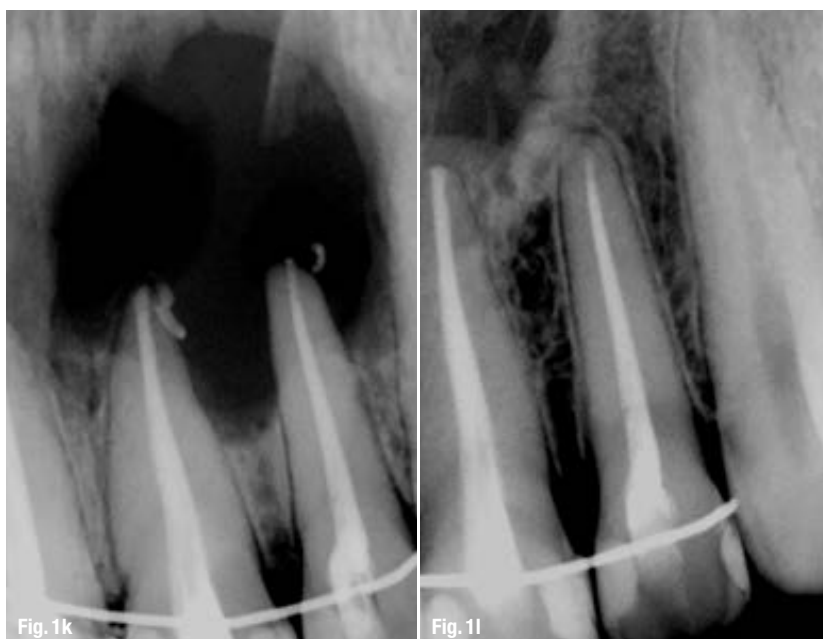What follows is zero apicectomy per se: following an intrasulcular or papilla-based incision (depending on the size of the lesion), a full-thickness triangular or rectangular buccal flap is raised. If the cyst has not perforated the buccal cortical plate, a round bur on an air-implanted handpiece is used to drill through the cortical bone and localise the cyst.

The cyst is spooned out with extreme care in order to preserve the cementum of the root and ligament fibres attached to the root surface.

When the totality of the cyst has been removed, the exposed part of the root surface is first rinsed with normal saline and then scrubbed with citric acid applied with a microbrush for 30 seconds.

**Figs. 1k & l:** Comparison of immediate postoperative radiograph (k) with 5-year follow-up (l).

The whole area is then rinsed abundantly with sterile water or normal saline, and the flap is temporarily put back in place without suturing.



The tooth or teeth are again isolated with rubber dam for the temporary filling to be removed and 'A' full sequence of irrigation with the use of EndoVac to be conducted again.

When this second cycle of irrigation is finished and the root canal is dried, a master cone is adjusted followed by a complete obturation of the root canal system with the warm vertical compaction technique.

A temporary filling material is then placed in the access cavity and the rubber dam is removed.

The final step consists of raising the flap up again and checking for any significant extrusion of the obturating material, which needs removing. When cleanliness of the wound is ensured, the flap is sutured in place with monofilament suturing material 5.0 and/or 6.0, and post-operative medication is prescribed (patients are instructed to continue the antibiotics for 7 days, to continue ibuprofen 400 mg/each 4 hours for the following 24 to 36 hours, and to start alcohol-free mouth wash rinses 24 hours after the procedure).

## Discussion

Apical periodontitis (AP) is an inflammatory/immune response in the apical periodontium that is often caused by intracanal microorganisms. The resulting apical bone resorption is a manifestation of the defense mechanism, preventing the spread of infection and appears radiolucent on radiographs.<sup>27,18</sup>

Because AP is usually asymptomatic, it is frequently only detected during routine radiographic examination.<sup>4</sup> In this sense, radiography is essential for the successful and timely diagnosis of AP, and it historically has been limited to periapical and panoramic radiographs.<sup>1</sup>



Furthermore, radiographic imaging is essential in all stages of endodontics from diagnosis to long-term assessment of healing outcomes. In conjunction with symptoms, outcome is assessed by comparison of preoperative and/or immediate postoperative radiographs with subsequent radiographs taken at follow-up appointments.<sup>13,20</sup>

The diagnostic value of pretreatment radiographs depends on how well they reflect the histology of AP. Studies that investigated the correlation between histological appearance and radiographic manifestations found that absence of radiographic signs does not exclude apical inflammation, and radiographic appearance is always smaller than the histological extent of the lesion.<sup>23,25-27</sup> Radiographic signs pathognomonic of AP include radiolucent changes in periradicular trabecular pattern and altered shape and width of the periodontal ligament (PDL) space.<sup>3,8,12,14</sup>

However, periapical radiographs and panoramic images have inherent limitations such as superimposition and distortion of important structures that commonly mask lesions.<sup>19,22</sup> Additionally, lesions in the cancellous bone cannot be consistently detected with these radiographic techniques.<sup>5</sup> Therefore, in some cases, extensive bone resorption may be present even when there is no radiographic evidence of it.<sup>5</sup> The appearance of the periapical tissues on a radiograph is influenced by the superimposition of anatomic structures and the variable nature of the overlying bone density and texture.<sup>13,20</sup>

These limitations of periapical radiography have led to significant interest in CBCT.

Currently, the use of CBCT has made it possible to visualize anatomical structures in 3 dimensions with higher resolution. This has improved the overall diagnostic efficacy and made early diagnosis possible for some specific clinical situations.<sup>26,31</sup> In endodontic practice, CBCT imaging with limited field of view (FOV) has been suggested for diagnostics in patients with contradictory or nonspecific clinical signs and symptoms.<sup>31</sup>

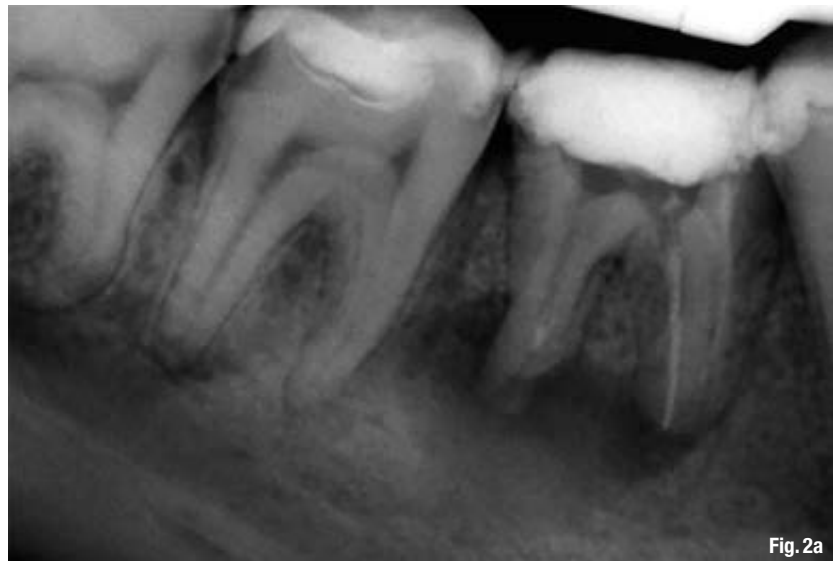

Fig. 2a

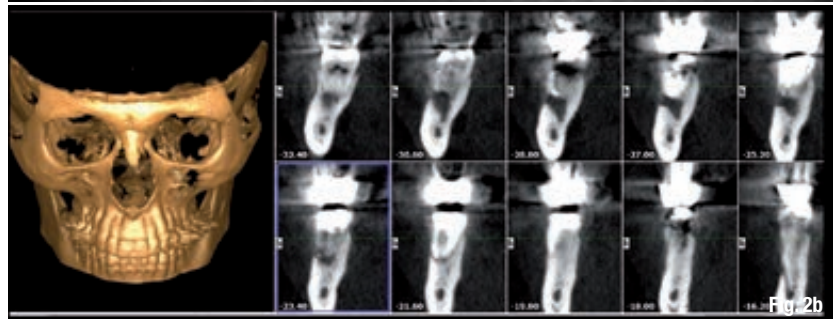


Fig. 2b

Postsurgical excisional wound healing following periradicular surgery entails dentoalveolar healing (i.e. reestablishment of an apical attachment apparatus) and alveolar healing (i.e. osseous repair of the trabecular and cortical bone).<sup>2</sup>

#### Case 2

**Fig. 2a:** Preoperative periapical radiograph.

**Fig. 2b:** CBCT data of the patient.

Cementum deposition on the root end is considered the critical step in dentoalveolar wound healing.<sup>2</sup> Consequently, creating an environment is conducive to cementogenesis should enhance the healing process following surgical endodontic treatment.

In periodontal surgery, demineralisation dentine leads to enhanced new connective tissue attachment through splicing of exposed dentinal collagen with new collagen fibres produced during wound healing

**Fig. 2c:** The cystic reaction in the vicinity of the mandibular canal.

**Figs. 2d & e:** Immediate postoperative radiograph (d) compared with the preoperative X-ray image (e).

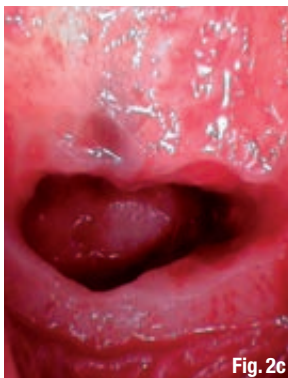


Fig. 2c

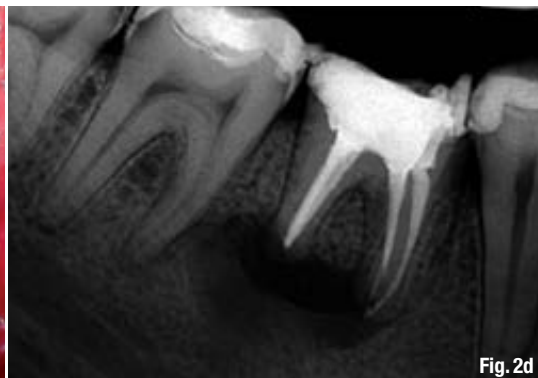
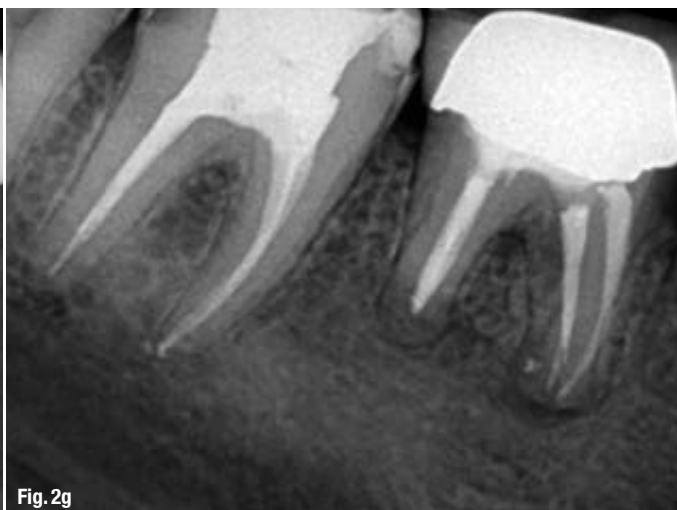


Fig. 2d

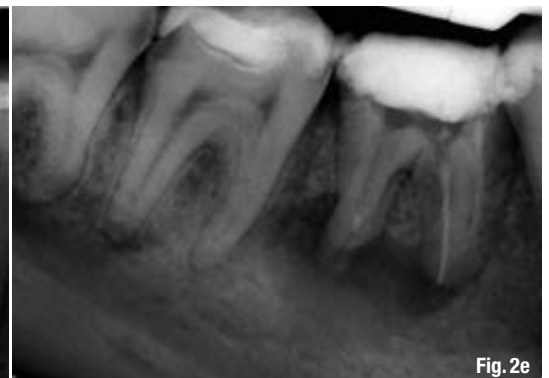

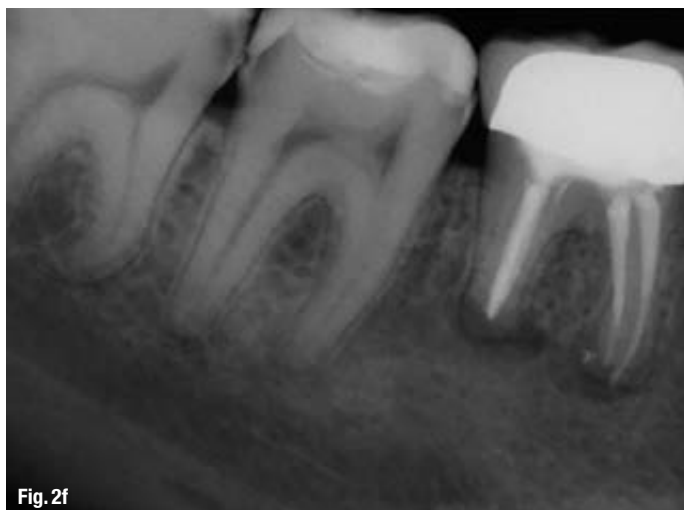Fig. 2e



**Fig. 2f:** One-year follow-up radiograph.

**Fig. 2g:** Two-year follow-up radiograph.

and early deposition of cementum on the dentinal surfaces.<sup>10</sup>

Demineralising the root surface with citric acid has been shown to increase cementogenesis and promote periradicular wound healing by exposing the collagen matrix, which stimulates fibroblast attachment and growth.<sup>10</sup>

When comparing citric acid with EDTA and citric acid alone in root conditioning, the latter has demonstrated the best results for smear layer removal and clot stabilisation. EDTA inhibited clot stabilisation on root surface and must have had a residual activity once it has diminished clot adhesion to root even after citric acid conditioning. Thus, EDTA can be used to neutralise citric acid effects on periodontal cells without affecting clot stabilisation, while citric acid use may favor clot stabilisation and may have a beneficial effect on surgical outcomes.<sup>24</sup>

Other researchers also indicated citric acid to stabilise clots on the root surface, which act as a scaffold for connective tissue cell development.<sup>21</sup>

### Case 3

**Figs. 3a–c:** Pre-operative radiographs: upper anterior teeth.

As for the manner of citric acid administration, better results for collagen exposure were obtained with

brushing application of 25% citric acid for 3 minutes than with other application parameters.<sup>9</sup>

The irrigation is conducted with a negative pressure device, EndoVac (Sybron Endo), as it ensures a safe delivery of irrigants to the apical terminus of root canals.<sup>25</sup>

The device consists of a delivery/evacuation tip attached to a syringe of irrigant and the high volume suction of the dental chair. With a macro- (in the coronal and middle third) or microcannula (in the apical third) attached to the suction device, the irrigant introduced into the pulp chamber is pulled by negative pressure down the canal into the tip of the cannula and removed through the suction hose thus avoiding any extrusion of the irrigant outside the root canal area where the PDL barrier is lost and thus the use of conventional irrigating methods could result in pushing the chemicals into the exposed surgical site.<sup>25</sup>

## Case reports

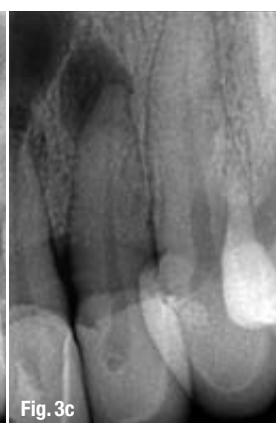
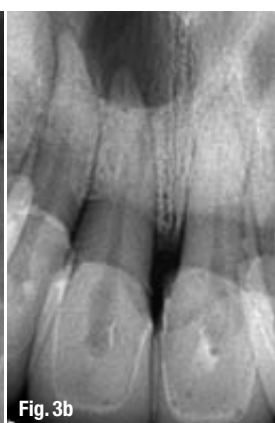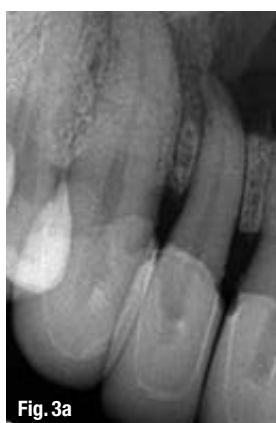Once there is a positive diagnosis of apical cyst, the patient is informed of the situation and the different steps of the treatment. When/if an informed consent of the patient is obtained, the treatment may begin.

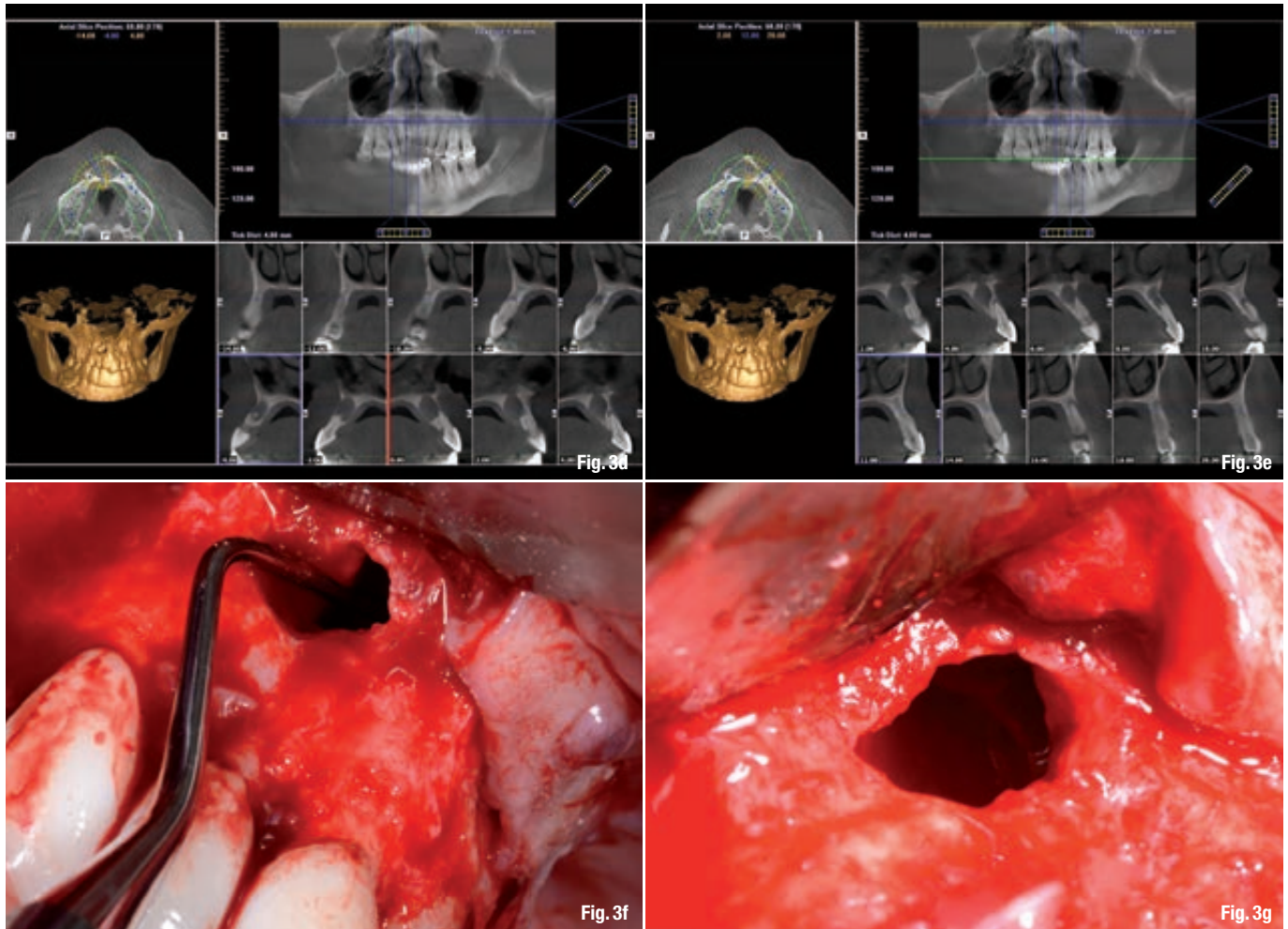
### Case 1

A female patient was referred to the clinic with a swelling on the palatal side in region of the upper lateral incisor on the left (Fig. 1a). Axial cuts of 3-DCBCT scans showed an extremely large area of bone loss at the apical level of the upper lateral incisor (Fig. 1c), as well as at the level of the two upper central incisors (Fig. 1d).

After administering anesthesia, a syringe was inserted in the palatal mucosa and a large amount of pus was aspirated.

Having performed the procedural steps of combined conventional RCT and zero apicectomy as described





previously and having removed the cyst, a long part of the roots remained exposed, especially that of the lateral and central incisor. The flap was sutured without any augmentation or grafting of the large defect.

An immediate postoperative radiograph was taken (Fig. 1e), and then a one-year follow-up radiographs (Figs. 1g & h) to assess the healing process.

The one-year follow-up shows the formation of a new bone around the teeth and the formation of a new PDL, while the 5-year follow-up radiograph (Fig. 1i) demonstrates no signs of external or internal root resorption, an intact PDL, and a smaller fibrous area, which altogether allows evaluating this outcome of the treatment as successful.

## Case 2

A male patient was referred to have his mandibular molar checked. It was essential for the patient to save his molar by all means, even though he had been advised to have it extracted and replaced by an implant.

The preoperative radiograph (Fig. 2a) shows a substantial periapical lesion though the previous dentist had placed calcium hydroxide paste in the canals.

Furthermore, the patient was complaining of tingling in his lower lip.

The i-CAT scan (Fig. 2b) showed the cystic reaction going deep internally and almost reaching the mandibular canal.

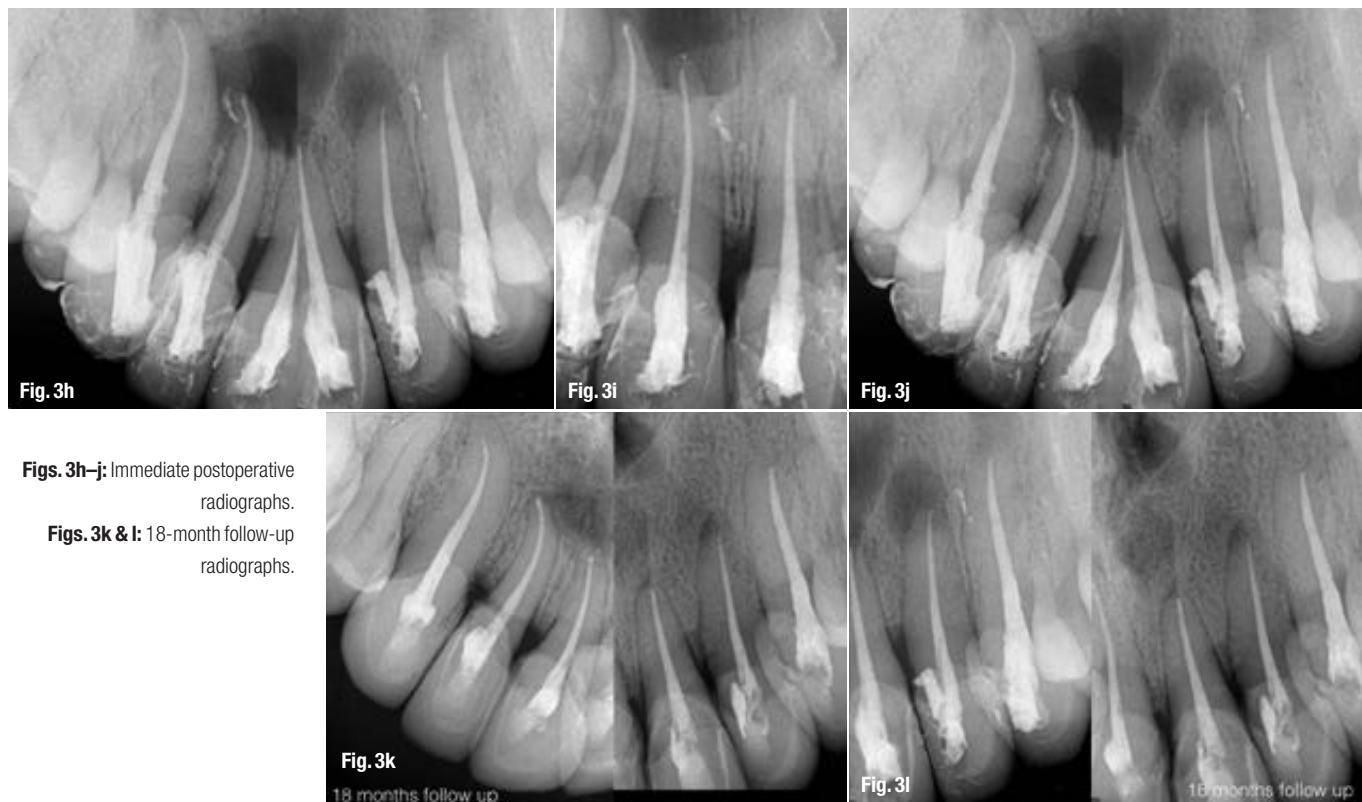The same approach, as described previously, was performed in an attempt to treat and save the molar. Once the flap was elevated, it appeared that the cyst was also present under the periosteum above the cortical bone, and there another cyst was found intra-operatively close to the mandibular nerve (Fig. 2c), which could be responsible for the lower lip sensation the patient reported.

Immediate postoperative X-rays (Figs. 2d & e) were taken upon the completion of the surgical and conventional root canal therapy, and a complete healing was seen in the follow-up radiographs after 1 and 2 years (Figs. 2f & g) with a full reconstruction of the bone. Moreover, within the first 3 weeks upon the treatment the tingling of the lower lip was resolved as well as other clinical symptoms.

**Figs. 3d & e:** CBCT scans.

**Figs. 3f & g:** Intraoperative photographs showing the defects resulting from the cystic reactions.





**Figs. 3h–j:** Immediate postoperative radiographs.

**Figs. 3k & l:** 18-month follow-up radiographs.

### Case 3

A male patient was referred to the clinic to check the status of his upper anterior teeth. The patient had received crowns several years before, and apparently the pulp of those teeth became necrotic, which led to periapical infections.

On the preoperative radiographs and on the i-Cat scans (Figs. 3a–e), periapical cysts could be easily identified along with massive bone loss.

A zero apicectomy approach was used as described earlier in order to treat all the upper anterior teeth and to remove the multiple cysts, while preserving the bone and roots as much as possible and only to use the bone defect that had been created by the infection to scoop out the cysts (Figs. 3f & g).

Immediate postoperative radiographs (Figs. 3h–j) were taken as well as radiographs for an 18-month follow-up (Figs. 3k & l).

Further follow-up turned out to be impossible as the patient has since been unavailable. However, the follow-up radiographs demonstrate a decrease in radiolucency, which allows us to assume that bone regeneration is in process, and a new PDL is in formation.

### Conclusion

Zero apicectomy in endodontic surgery is a novel technique that implies the use of high-resolution

CBCT visualisation of the apical situation (alongside with traditional radiological and clinical evaluation) with conventional root canal treatment including the safe and efficient negative pressure irrigation, and root surface conditioning in order to allow for the preservation of the apical part of the root ad integrum and for the restoration of periodontal health. Biologically, the technique's foundation lies in the thorough cleaning of the root canal system and the area of the cystic reaction, while preserving the residual structures of the root and periodontium and creating conditions for reattachment and regeneration. It also follows the modern philosophy of the minimally invasive dentistry, where less turns out to be more.

Current literature has not described this technique; however, clinical cases, including those presented in this article, have proven successful outcomes of its application.

### authors

#### Dr Randa Harik

Clinical instructor, Dental School, Lebanese University.  
Dr Grace Issa Clinical instructor, Dental School, Lebanese University.

#### Prof. Philippe Sleiman

Assistant & Professor, Dental School, Lebanese University; Adjunct Associate Professor, Dental School, University of North Carolina.

*\*Zero apicectomy is indicated predominantly in teeth where conventional root canal therapy (initial or retreatment) can be performed in an orthograde fashion and preferably in the same session; in the cases where conventional retreatment is impossible or would unreasonably weaken the tooth (such as presence of post and crown or post-and-core and crown), regular apicectomy would be a more effective mode of treatment to reduce the bacterial load in the apical third and to seal the area.*