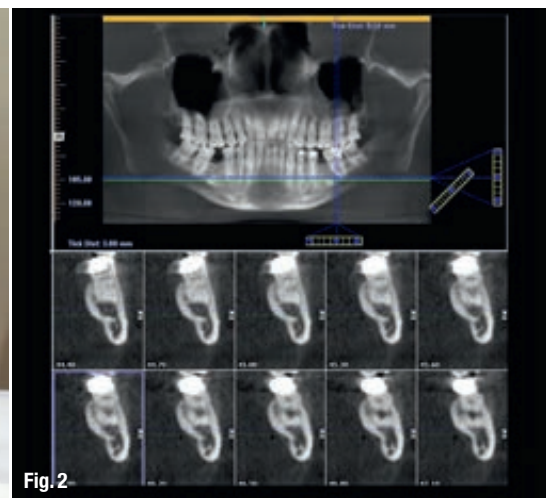
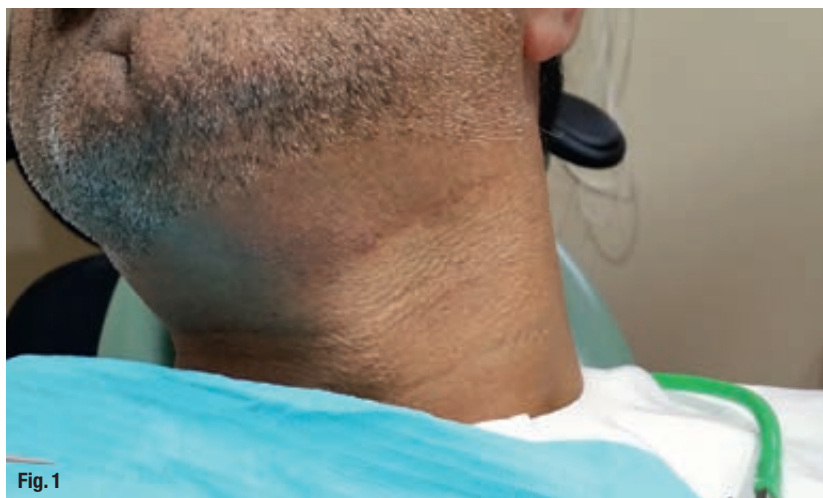

“Find it, fix it, and leave it alone”¹

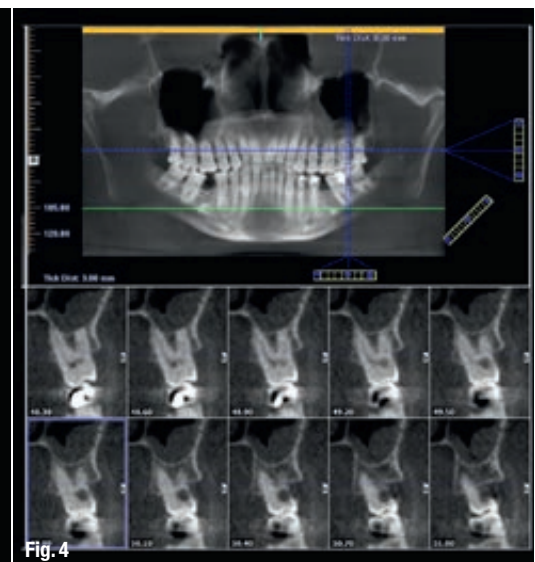
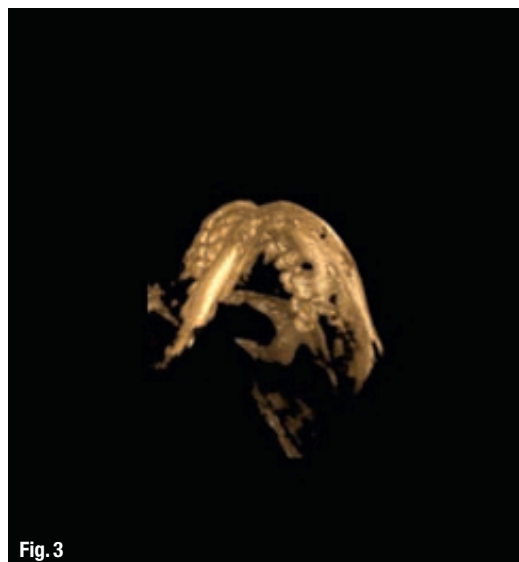
Author: Prof. Philippe Sleiman, Lebanon



This **three-part principle**, though originating in the field of osteopathy, can find great application in modern endodontics, where we deal with routine root canal treatment, as well as with cases in which a patient is in a compromised state of health for which the solution may be a routine root canal treatment, and anything more than that would be overtreatment.

Initially, we need to find the problem, by analysing the clinical situation and identifying what is going wrong. This task is truly difficult: making the correct diagnosis based on

- the patient's account; here, we need to listen to our patient, to learn about his or her local problem, where it is located and what triggers it



- the patient's history, that is overall health, any diseases and/or conditions, systemic medication, etc.
- the proper use of the appropriate diagnostic tools, including pulp testing, response to cold and hot, the bite test, radiographs and CBCT scans; additionally, the latest software can help us in reading and analysing the data that we have, including in 3-D—I recall the words of my radiology professor, reminding us to study radiographs and be attentive to every small detail, not just look at them
- the logical connection between the patient's account and history, the clinical findings and the imaging data—sometimes, putting the pieces of the puzzle together can be fast; sometimes, it may take longer.

Once the diagnosis has been established, the choice of treatment modality and selection of the best tools to perform the treatment follow. At this stage, focusing first and foremost on the patient's health, it is important to choose the most effective and efficient treatment that would be as minimal as is practical and sufficient. The rest should be taken care of by Mother Nature.

Case presentation

Case 1

The first case that I would like to present was a referral patient. Sitting back in the chair, the patient started giving his account: over the previous six months, he had twice travelled to somewhere in Asia for surgery on his left-sided submandibular lymph nodes (Fig. 1), which had apparently been swollen. Each time, pathology tests were clear of any cancer-specific markers. CT scanning and conventional radiographic assessment were conducted, with no findings recorded.

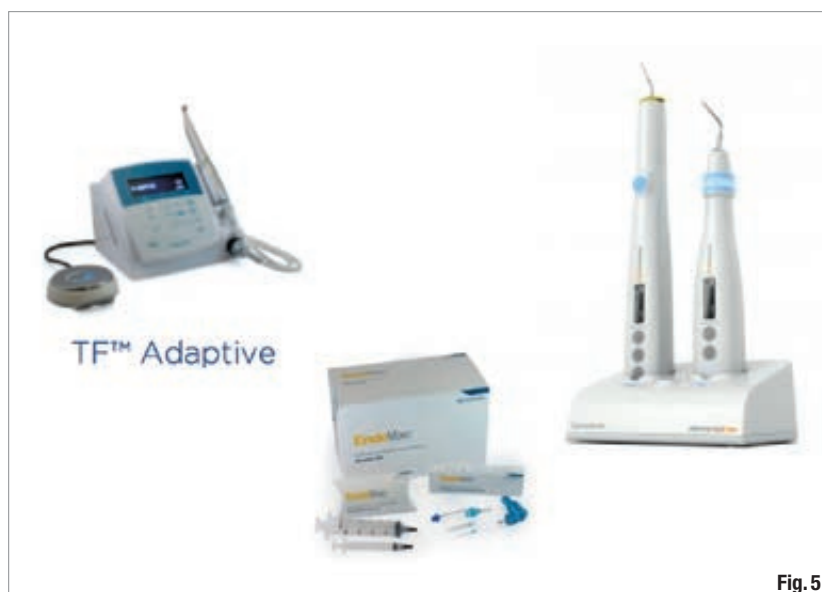

Fig. 5

Having shared this, the patient reported that he felt his lymph node becoming swollen again, and he was anxious about it. His account was taken very seriously. Additionally, he reported that two of his mandibular premolars were aching, since root canal treatments had been started at a different clinic, but the dentist had been unable to finish them. With the patient's permission, a new CBCT scan was obtained, and I asked the patient to wait for an hour to give me time to study it.

Judging by the general view first and then going into local details, I realised the two mandibular premolars were indeed in need of endodontic retreatment. However, knowing from clinical experience that premolars may have various clinical manifestations, I continued looking for other sources of potential problems, but without disregarding the premolars as the culprits (Fig. 2).

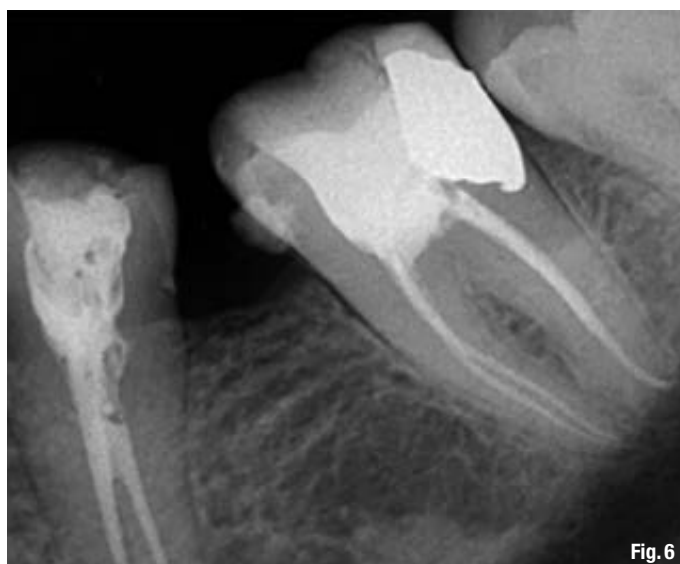

Fig. 6

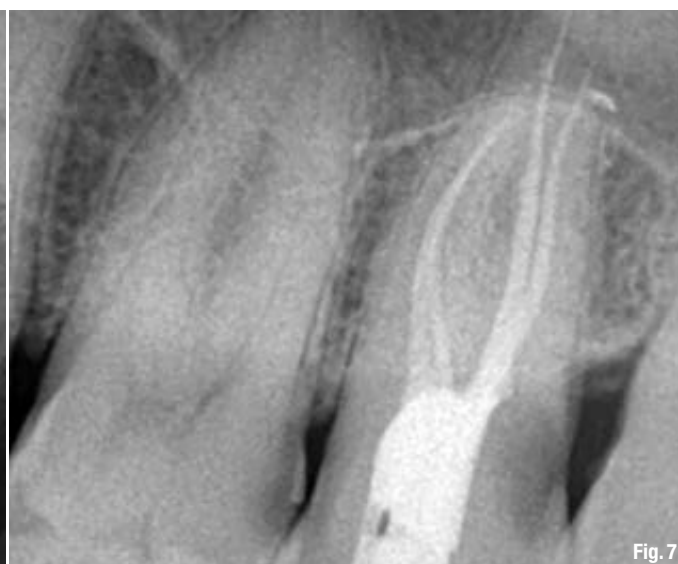

Fig. 7

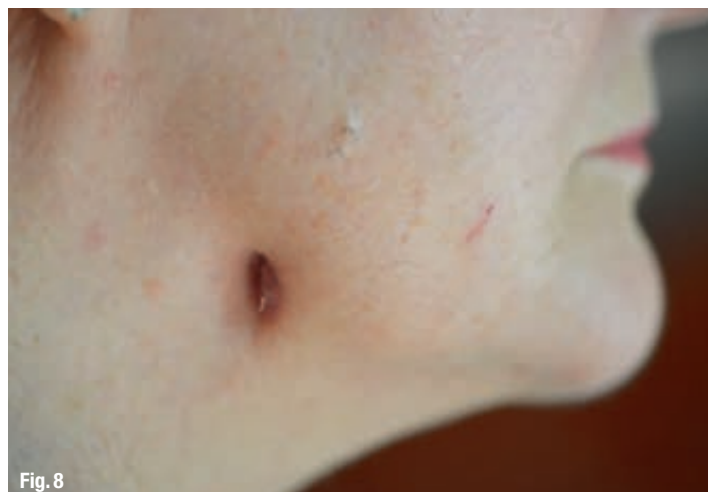

Fig. 8

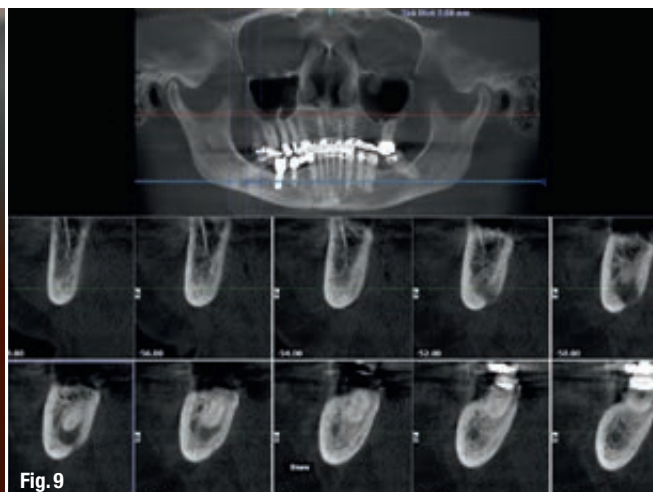


Fig. 9



Analysing the CBCT sections, trying different filters and settings, looking at the mandibular molar with a large filling, and studying the bone around it, my eye caught something unusual. There was a **small abscess migrating towards** the internal angle of the mandible (Fig. 2) and creating an area of bone erosion (Fig. 3). This could be the pathology causing the patient's suffering, in addition to the two mandibular premolars.



At this point, **one might be happy with the diagnostic findings** and race to treat the problems affecting the mandibular dentition. However, still unsatisfied with the overall findings, I turned to analysing the maxilla, where I found that the second molar had internal decay **and** cervical internal resorption, creating an infection pathway into the maxillary sinus (Fig. 4).

I explained the situation to the patient and proposed retreating the two mandibular premolars, as

well as conducting primary root canal treatment on the mandibular molar and the maxillary molar. The patient agreed, and the four treatments were performed in one session, using the TF Adaptive system (Kerr) for shaping and EndoVac (Kerr) for chemical preparation according to the "A" sequence of irrigation protocol,² followed by 3-D obturation of the root canal system using the Elements Obturation Unit (Kerr; Fig. 5). Antibiotics were prescribed for the patient to help his body combat the submandibular infection. Although I prescribe systemic antibacterial medication very rarely, I did so in this case because it was not clear what had happened with the lymph nodes and if they were still functional **based on the** immediate postoperative radiographs of the mandibular molar (Fig. 6) and the maxillary molar (Fig. 7). A minor postoperative reaction (moderate pain, no swelling) was observed and had completely resolved a week later.



Case 2

The next clinical case is somewhat similar and involved an extra-oral sinus tract (Fig. 8). A middle-aged female patient was referred to the office with an extra-oral fistula in the posterior submandibular area. According to the patient, she had had no pain or swelling and the fistula had appeared several weeks before she presented to the clinic.

At first, she thought it was a skin problem, but then realised that there was pus draining and the opening was growing larger. Upon consulting with a dermatologist, who said the problem was most probably of dental origin, the patient consulted her dentist, who had previously placed an implant for her. The dentist thought the infection was associated with her third molar and not the implant, and suggested extraction of **the tooth**. The patient wanted to retain the tooth and hence sought an endodontic consultation regarding this option.

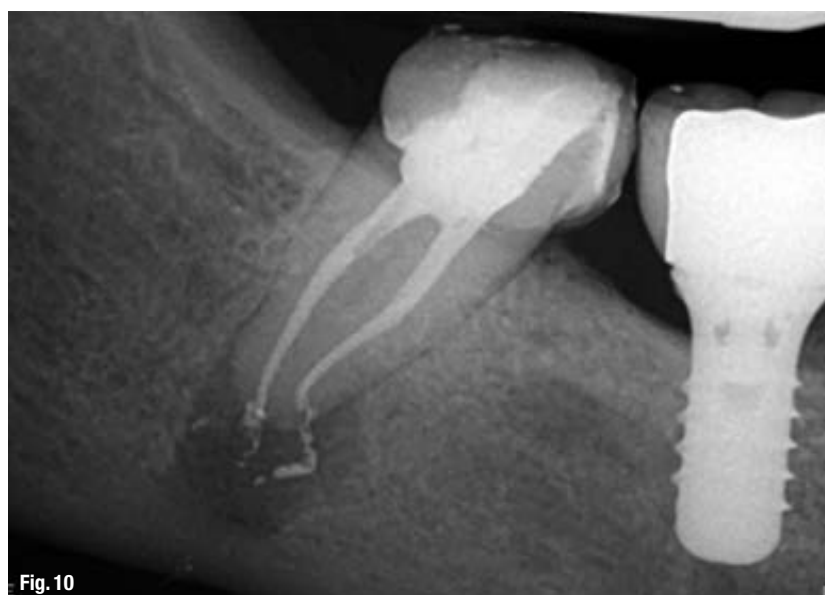

Fig. 10

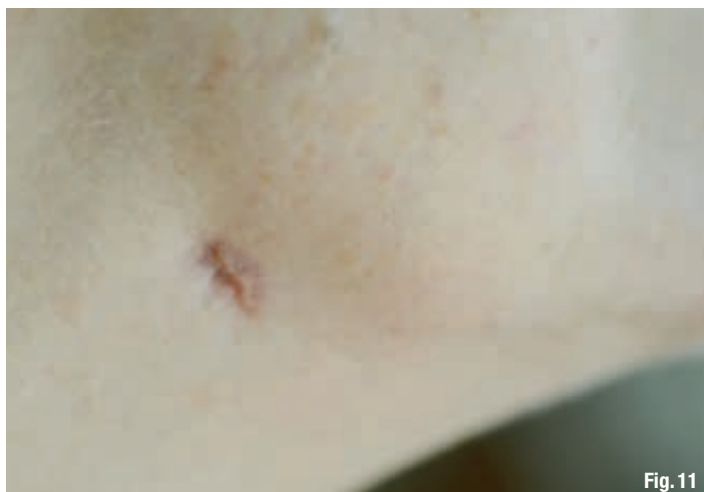

Fig. 11

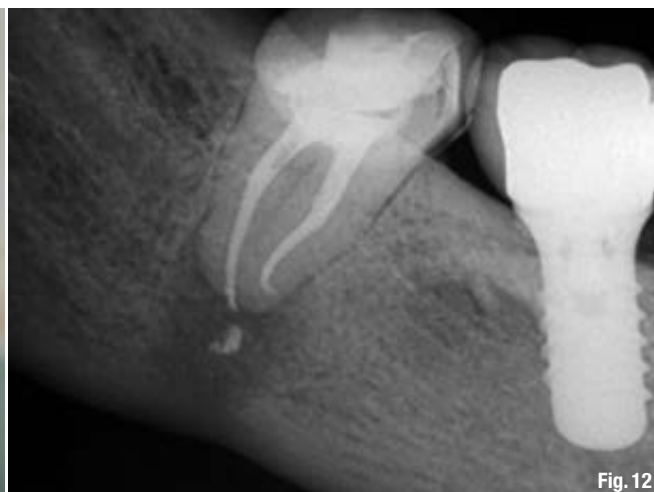

Fig. 12



A new CBCT scan (i-CAT, **Imaging Sciences International**; Fig. 9) confirmed that the third molar had an internal sinus tract, which had created the fistula. This could all be solved by root canal treatment on the molar, followed by a crown and follow-up treatment, with a good prognosis for overall long-term success. The patient was happy to hear that and requested treatment as soon as possible.

The root canal was treated (Fig. 10), using the TF Adaptive system for shaping and EndoVac for chemical preparation according to the "A" sequence of irrigation protocol, followed by 3-D obturation of the root canal system using the Elements Obturation Unit (Fig. 5). Follow-up records were taken (Figs. 11 & 12), with radiographic control to check for bone healing and external facial photographs to compare. The patient was extremely satisfied that her molar could be preserved.

Conclusion



These clinical examples illustrate the importance of diagnosis as the main piece of the puzzle the importance of "finding it". Today, the state-of-the-art approach in endodontics requires the use of sophisticated equipment and software to complement the expertise and experience of the operator. Only all this in concert allows us to put the pieces of the puzzle together.

The patient's subjective account can lead us or sometimes mislead us. We should keep in mind that most of our patients do not know how anatomy works or that pain can be referred from a distant area in the mouth. That is where the objective history and adequate analysis of the diagnostic and clinical findings lead the way.

Fixing the problem requires the most biological approach to root canal treatment, putting our clinical

experience to work to provide the best treatment for our patients. Once we are sure we have done the best we can to eliminate all kinds of **aggressive conditions and disease**, we need to let nature take care of the healing process.

Acknowledgement: The author would like to thank Yulia Vorobyeva Sleiman, interpreter and translator, for her help with this article.

References

- [1] "Find it, fix it, and leave it alone"—an axiom attributed to Dr Andrew Taylor Still, the founder of osteopathy, and recorded by his students and followers.
- [2] Published earlier in Sleiman, P., "A' sequence of irrigation", *roots international*, 1 (2014), 14–7.

author



Dr Philippe Sleiman

is an endodontist at the Vilafortuny clinic and training centre in Dubai in the UAE, the Advanced American Dental Center in Abu Dhabi in the UAE and the American Dental Clinic in Dubai. He can be contacted at profsleiman@gmail.com